

Surgical Treatment of Chronic Lower Extremity Neuropathic Pain

*Lew C. Schon, MD; Claude D. Anderson, MD; Mark E. Easley, MD;
Peter W. C. Lam, MD; Hans-Jörg Trnka, MD; David B. Lumsden, MD;
Gail Levin, RN; and Jai Shanker, MCh*

The current authors retrospectively reviewed 147 lower extremity peripheral nerve procedures in 114 patients (average age, 42 years) with chronic lower extremity neuropathic pain to determine whether surgical treatment based on an empirically derived algorithm could reduce pain and improve function. This algorithm assigns crush, stretch, and chronic transection injuries to treatment with transection and containment. Peripheral nerve stimulation was used in conjunction with transection and containment for patients with more chronic presentations for whom previous transections had been unsuccessful. Patients with adhesive neuralgia underwent revision neurolysis with vein wrapping. Patients with repetitive nerve trauma (overuse) underwent primary or revision neurolysis. Duration of symptoms averaged 37 months, and mechanisms of nerve injury included chronic transection, crush, adhesive neuralgia, stretch, repetitive trauma, and idiopathic etiology. Time to followup averaged 38 months. Pain and dysfunction were ranked from 0 points

(no pain or dysfunction) to 10 points (pain prompting request for amputation or functional deficit warranting wheelchair use); preoperative and followup work status were documented. Average pain and dysfunction scores improved: 8.8 to 5.6 points and 7.6 to 5.0 points, respectively. Of the 114 patients, 52 (46%) patients improved their work status, including 35 of 87 (40%) involved in workers' compensation. There were no statistically significant differences in outcome based on mechanism of nerve injury or type of procedure. The consistent average improvement suggests this algorithm assigns the appropriate procedure to a given mechanism of injury.

The treatment of chronic intractable lower extremity neuropathic pain is challenging. The etiologies of such nerve pain are classified as crush, stretch, transection, compression, repetitive microtrauma, metabolic, and idiopathic. Sometimes there are multiple contributing factors, especially when several nerve surgeries have been done.

Treatment begins with nonoperative options, including medications, physical therapy with desensitization modalities, external electrical stimulation, and nerve blocks. If all reasonable nonoperative options fail, surgery is required. Surgical techniques include neurolysis, revision neurolysis, transection (with or

From the Department of Orthopaedic Surgery, The Union Memorial Hospital, Baltimore, MD.

Reprint requests to Lew C. Schon, MD, c/o Lyn Camire, MD, Editor, Orthopaedics, The Johnston Professional Building, No. 400, 3333 North Calvert Street, Baltimore, MD 21218.

Received: April 17, 2000.

Revised: May 5, 2000; October 17, 2000.

Accepted: November 3, 2000.

without containment procedures), barrier procedures (vein wrapping), and peripheral nerve or spinal cord stimulation.

The purpose of the current study was to review the results of the senior author's (LCS) experience with surgical treatment of chronic lower extremity neuropathic pain. The current authors hypothesized that surgical intervention based on an empirically derived algorithm could reduce pain and improve function in patients who had undergone unsuccessful previous treatment.

MATERIALS AND METHODS

One hundred forty-seven lower-extremity, peripheral-nerve procedures done in 114 patients from 1990 to 1997 were reviewed retrospectively. The 61 female and 53 male patients had an average age of 42 years (range, 17–77 years). Mechanisms of nerve insult included transection (37 patients), crush (35 patients), adhesive neuralgia (25 patients), stretch (22 patients), repetitive trauma (12 patients), and idiopathic etiology (13 patients). Patients with simple nerve entrapment or compression were excluded (there were no primary tarsal tunnel syndromes or Morton's neuromas).

For all 114 patients, nonoperative treatment, including medical therapy (with tricyclic antidepressant medications and antiepileptic drugs^{28,29,42,46}), physical therapy and desensitization techniques,^{16,17} therapeutic nerve blocks,^{6,11,40} and external electrical stimulation,^{24,25} had failed to relieve their intractable lower extremity neuropathic pain. These nonoperative measures were not repeated if they had been used appropriately before referral to the authors' institution. The number of previous nerve operative interventions (including neurolysis, revision neurolysis, transection, anastomosis, neuroma containment, and nerve barrier procedures) averaged 2.3 (range, 0–12 procedures) per patient.

Evaluation at initial consultation included clinical evaluation and electrodiagnostic studies. A careful history and physical examination were done for all patients. The history focused on evidence of systemic disease, mechanism of nerve insult, and specific nerve involvement. The results of previous surgical interventions were assessed to identify pain because of adhesive neuralgia, which may benefit from vein wrapping, rather than peripheral nerve stimulation.³⁷ Peripheral examination identi-

fied specific nerve involvement and sites of potential nerve injury (surgical scar and trauma). Pain and dysfunction were ranked from 0 points (no pain, no dysfunction, respectively) to 10 points (pain prompting request for amputation or functional deficit warranting wheelchair use, respectively); preoperative and followup work status were documented.

Electrodiagnostic studies were done in all patients to rule out systemic disease (contributing to a peripheral neuropathy), identify intraneural damage, find more proximal areas of nerve compromise (double crush phenomenon), or to determine if there was nerve compression or intraneural damage. Assessment included sequential nerve blocks with lidocaine and bupivacaine, beginning at the most distal site of suspected nerve disease and advancing more proximally.

Procedures occasionally involved more than one nerve: tibia, including branches, 113 cases; superficial peroneal, 27 cases; sural, 27 cases; interdigital, 14 cases; deep peroneal, 10 cases; and common peroneal, two cases. Procedures included transection and containment (61 cases), revision neurolysis with vein wrapping (37 cases), peripheral nerve stimulation (25 cases), primary neurolysis (12 cases), and revision neurolysis (12 cases). The surgical treatment algorithm (Fig 1) is complex, but in its simplest form, assigns crush, stretch, and chronic transection injuries to treatment with transection and containment, with or without peripheral nerve stimulation; adhesive neuralgia, to revision neurolysis and vein wrapping; and repetitive trauma, to primary or revision neurolysis. One surgeon performed all procedures.

One-way analysis of variance (ANOVA) was used to identify significant ($p < 0.05$) differences among the groups.

RESULTS

Retrospective followup was available for all 114 patients. Time to followup averaged 38 months (range, 24–96 months). Overall, pain scores improved from a preoperative average of 8.8 points (range, 5–10 points) to 5.6 points (range, 0–10 points) at followup. Dysfunction improved from a preoperative average of 7.6 points (range, 2–10 points) to a postoperative average of 5 points (range, 0–10 points). Of the 114 patients, 52 (46%) improved their

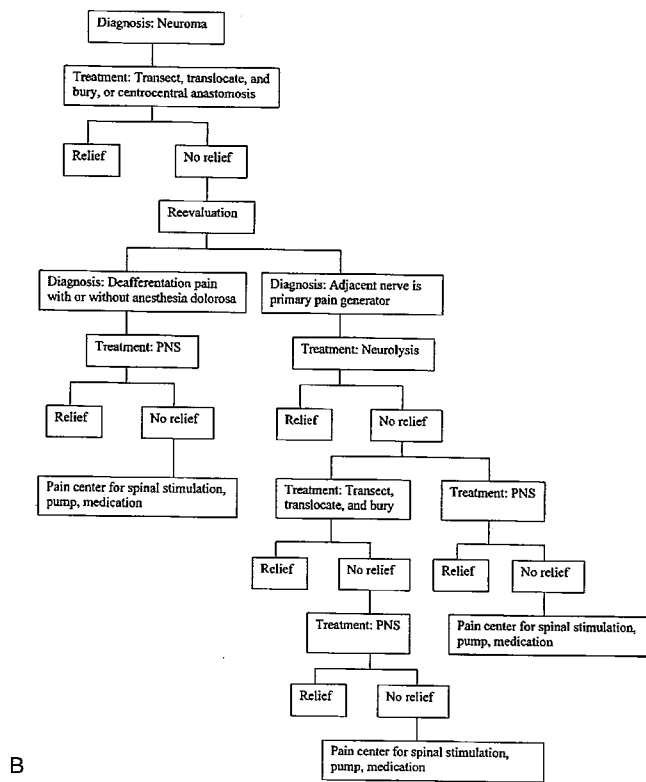
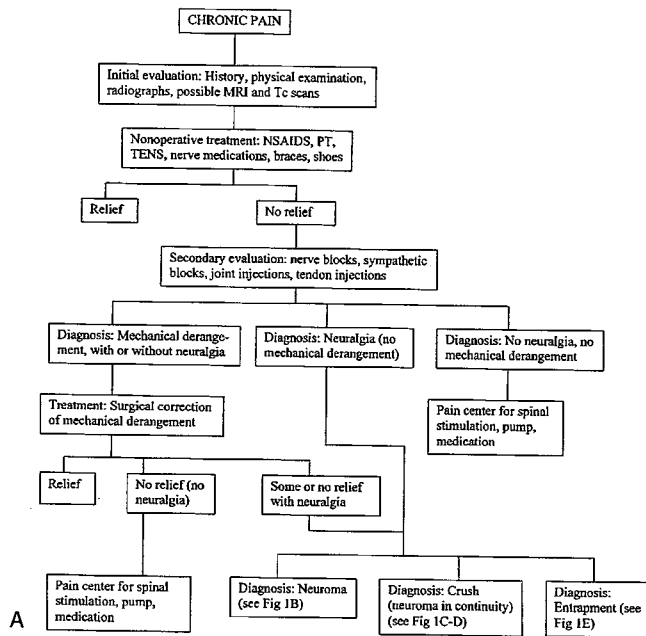


Fig 1A-B. Algorithm for treatment of chronic pain. (A) Initial evaluation and diagnoses. (B) Diagnosis of neuroma MRI = magnetic resonance imaging; NSAIDS = nonsteroidal antiinflammatory medications; PNS = peripheral nerve stimulation; PT = physical therapy; Tc = technetium; TENS = transcutaneous electrical nerve stimulation. (*continues*).

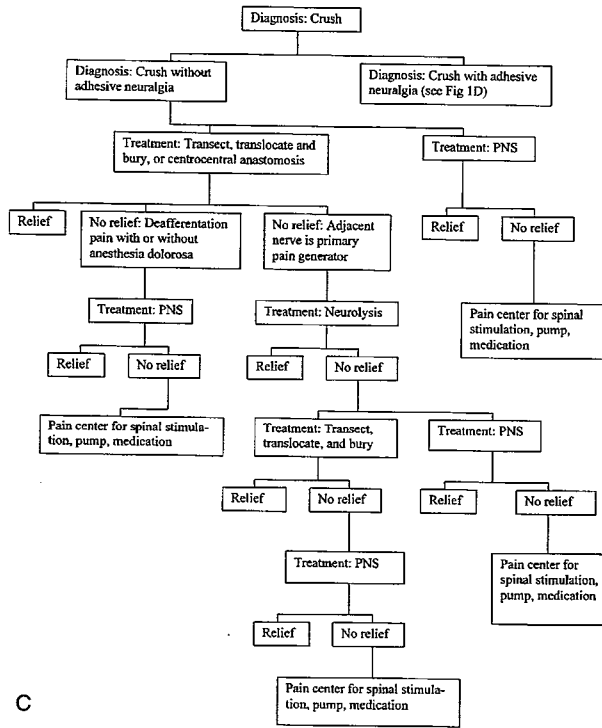
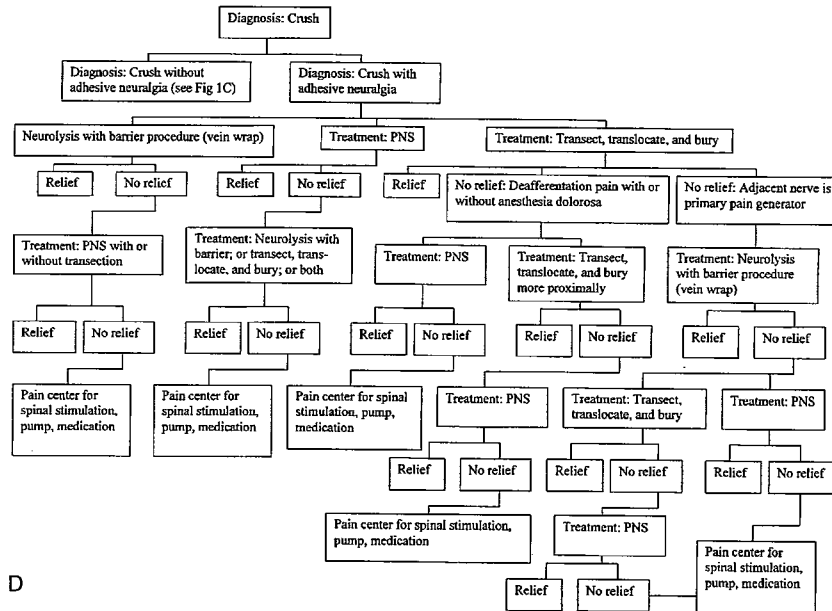


Fig 1C–D. (continued) (C) Diagnosis of crush without adhesive neuralgia. (D) Crush with adhesive neuralgia MRI = magnetic resonance imaging; NSAIDS = nonsteroidal antiinflammatory medications; PNS = peripheral nerve stimulation; PT = physical therapy; Tc = technetium; TENS = transcutaneous electrical nerve stimulation. (continues).



D

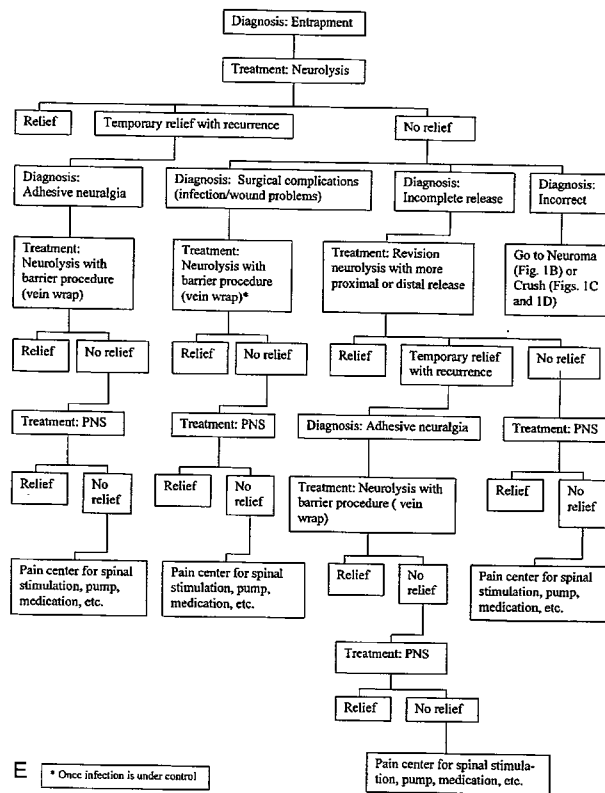


Fig 1E. (continued) (E) Diagnosis of entrapment. *, once infection is under control. MRI = magnetic resonance imaging; NSAIDs = nonsteroidal antiinflammatory medications; PNS = peripheral nerve stimulation; PT = physical therapy; Tc = technetium; TENS = transcutaneous electrical nerve stimulation. (Modified with permission from Schon LC, Easley ME: Chronic Pain. In Myerson, MS (ed). Foot and Ankle Disorders. Vol 2. Philadelphia, WB Saunders Co 851-881, 2000.)

work status, including 35 of 87 (40%) patients receiving workers' compensation.

Analysis of variance revealed no statistically significant differences in outcome based on mechanism of nerve injury or type of procedure.

DISCUSSION

Treatment of chronic intractable neuralgia, pain in the distribution of a nerve that does not respond to nonoperative or operative treatment, presents a difficult and challenging problem. Such pain involves primary nerve disease and encompasses a wide spectrum of causes involving internal nerve damage (stretch or crush injury) or external nerve damage (entrapment, mass effect), or both, often with contributing biomechanical factors (malalignment, instabil-

ity).³⁶ Any musculoskeletal problems that could exacerbate the chronic pain should be addressed nonoperatively (with braces, nonsteroidal anti-inflammatory medication, injections) or operatively (with ligament reconstruction or arthrodesis for instability). Any nerve problems should be addressed with nonoperative modalities; if nonoperative treatment fails, surgical options may be considered. Extrinsic or intrinsic nerve conditions may respond to primary or revision releases³⁹ or transection and burial techniques.^{2,4,5,7,9,10,13,14,18-21,27,32-34,43,44,47,50} Containment procedures, such as centrocentral anastomosis or nerve capping, can decrease the likelihood of a painful neuroma by containing or controlling rejuvenant nerve growth after transection.^{2,3,12,14,23,34,43} Barrier procedures, such as fat grafts, fascial flaps, and vein wraps, are used for adhesive neuralgia (painful nerves en-

trapped in scar tissue) and can insulate compromised nerves from external scarring.^{8,15,25,26,41} Peripheral nerve stimulation or spinal cord stimulation can modulate neurologic response, diminishing nociception.^{22,30,31,38,45,48}

The choice of what procedure is best must be individualized to the patient, depends on many factors, and often is difficult. If the neurogenic pain continues regardless of treatments such as those listed, several options remain, including an indwelling pain pump¹ and amputation with or without continued pain medications and nerve blocks.

The aim of the current study was to analyze the authors' treatment algorithm (Fig 1), which assigns the appropriate procedure to a given mechanism of injury in a patient with intractable lower extremity neuropathic pain. To choose which patient would benefit from these procedures, it is important to differentiate among extraneural disease (adhesive neuralgia), intraneural conditions, and combinations thereof because the treatment options will differ. This differentiation is accomplished through a careful history and physical examination.

Historically, it is important to review the inciting event and previous treatment. Stretch injury, neuroma, or neuroma in continuity all suggest intraneural disease. A patient with a neuroma or neuroma in continuity will report an area of lost sensation coupled with a more proximal hot spot or trigger point that, if brought into contact with a shoe, brace, or the ground, results in a burst of pain. Spontaneous or ectopic neuralgia (pain not induced by movement, position, or activity) suggests internal nerve damage. Nociceptive neuralgia, pain that follows after introduction of some form of stimulus, may be seen with internal or external disease. Primary entrapment or infection after neurolysis (resulting in scarring) suggests an extraneural condition. Crush injury tends to cause intraneural and extraneural conditions. Response to bracing may indicate an extraneural problem because bracing should be of little benefit for patients with intraneural disease. Adhesive neuralgia is suggested when a patient gains temporary relief of

symptoms with a neurolysis and then experiences a recurrence of symptoms weeks or months later. However, if no relief was obtained, the pain may be a result of an incomplete release, excessively aggressive release resulting in intraneural damage, or release for the wrong indication (such as wrong nerve or a missed lesion).

A physical examination that reveals a diffusely painful scar with worsening nerve symptoms during range of motion (ROM) of the adjacent joint (ankle) suggests adhesive neuralgia. A free ROM of the adjacent joint and a mobile, nontender scar is not likely to be associated with adhesive neuralgia. Signs of neuroma or neuroma in continuity, such as zones of numbness or a focal positive percussion test, suggest intraneural disease. A deafferentation phenomenon after intraneural damage is manifested clinically by an area of decreased dysesthesia and hyperpathia. It is not uncommon in such patients to find tenderness over adjacent nerves despite evidence that the nerves were not primarily injured. Anesthesia dolorosa, an area of decreased touch sensation that is extremely painful to touch, is another deafferentation syndrome indicative of intraneural disease. The neurophysiology of anesthesia dolorosa is not clearly understood. It may represent an alteration of the gate mechanism of pain. The gate mechanism theory proposes that pain carried by the sensory nerves from the periphery is controlled by gates. These gates are opened when only pain signals are received but closed when there is other, competing nonpain sensory information (light touch) to convey.^{30,35} In these cases, the absence of afferent input permits an augmentation or disinhibition of the damaged and adjacent C-unmyelinated pain fibers. This afferent imbalance promotes the carrying of the afferent signals by the alternative pathways. Thus, the light-touch stimulation is perceived by the nociceptors, rather than the light-touch afferent receptors, and ultimately processed as pain signals.

Electrodiagnostic studies may be helpful in documenting the nerve disease. Decreased

amplitude and prolonged distal latencies support extraneural compression. Electromyographic changes with evidence of denervation support intraneural disease or axonal damage. However, normal electrodiagnostic studies may occur with intraneural and extraneural conditions.⁴⁹

Currently, electrodiagnostic studies offer little predictive value regarding prognosis or choice of intervention in the treatment of chronic pain. Findings at the time of surgery also may help determine which procedure should be done. If the plane between the scar tissue and the nerve is easily dissectible and macroscopically normal and there is evidence of a previously incomplete release, revision neurolysis can be successful. If there is dense scarring on the nerve with a normal looking nerve after neurolysis, vein wrapping alone is beneficial. However, if these findings are seen without a history of transient relief after previous neurolysis, peripheral nerve stimulation may be indicated. If the nerve is scarred and seems abnormal and there is a history of transient relief after neurolysis, a combination of peripheral nerve stimulation and vein wrapping may be indicated. (This hypothesis currently is under investigation.) However, if these operative findings are seen without a history of benefit after neurolysis, peripheral nerve stimulation alone is indicated.

In general, in patients with repetitive trauma, the nerve is affected by multiple recurrent ministretches or minicompressions that occur during activity. Typically, it is affected by a surrounding anatomic structure, such as a fascial edge, adjacent muscle belly, or prominent bone, and the patient begins to experience neuralgia. In such a situation, especially early in its course, there is little to no internal nerve damage; it primarily is an external nerve problem. Thus, for cases that are chronically painful, a release of the nerve to stop the compression or stretches is warranted and would be logical as a means for reducing the instigating factor. However, when a primary release does not alleviate the pain, a revision neurolysis with a broader zone of de-

compression of the nerve is recommended. If excessive bleeding occurred during the previous surgeries, if infection has developed, or if the bed of tissue around the nerve is unhealthy, recurrent external scarring is more likely the etiology for failure. In such cases, the patient may manifest an adhesive neuralgia (where the nerve is scarred to its surrounding bed), for which a revision nerve release followed by a barrier procedure (vein wrap) to prevent the external scar from encroaching on the nerve would be recommended. Still, the extent of the nerve damage in cases of repetitive trauma or adhesive neuralgia determines the benefit of surgery. If the internal nerve damage is substantial, external releases and barrier procedures, such as vein wrap, still would be recommended, but the prognosis would be less favorable.

In a stretch injury, the nerve is injured internally, but there usually is little injury to the surrounding bed. Often, there is no persistent anatomic structure that continues to stretch the nerve. Thus, because eliminating any external factors by performing a nerve release is low risk but would be expected to be of limited benefit, a stretch injury that results in chronic intractable neuralgia may be treated best with a transection of the nerve (with or without burial or containment procedures) or peripheral nerve stimulation. In the current authors' experience, some patients with stretch injuries did well with transection and containment, but for several patients this procedure provided no relief, and in some patients, pain was increased. These patients subsequently had peripheral nerve stimulation with good results; some persistent symptoms were thought to be a result of the previous transection (deafferentation phenomenon or anesthesia dolorosa). Thus, the authors' current surgical recommendation for a patient with intractable neuralgia from a severe stretch injury is peripheral nerve stimulation because it is a less destructive and less irreversible method of treating the problem.

In crush injuries, the nerve and its external tissue environment are traumatized. The ex-

tent of the trauma is variable, and some nerve trunks or branches are affected more than are others. Performing transection with containment of severely damaged nerves or branches or peripheral nerve stimulation, or both, has been successful. Patients for whom transection and containment alone was unsuccessful had good response to subsequent peripheral nerve stimulation, provided there were no additional complications from the transection. In the current series, the crushed nerve, neuroma, or neuroma in continuity in a mechanically vulnerable region (such as the sole or dorsum of the foot) that was subjected to recurrent stresses was treated with transection and burial more proximally, out of the zone of trauma. However, for patients in whom the zone of trauma was not vulnerable and in whom pain was present, regardless of external stimulus, peripheral nerve stimulation was the recommended treatment.

Chronic transection injury can manifest as two types of symptom complexes. One type of system complex is ectopic neuralgia, in which the patient's nerve has been cut spontaneously and discharges, causing severe pain. In such patients, more proximal transection and burial may not provide relief if the end of the nerve has not been triggered by an external surface, such as a shoe, the ground, or an adjacent structure. Such cases also may be associated with the deafferentation phenomenon or anesthesia dolorosa, which, according to the current study, does not respond to higher transection and burial because the gate mechanism of pain (that created the deafferentation phenomenon) is not altered. Thus, for such cases, peripheral nerve stimulation would be a better alternative than transection and burial. The second type of symptom complex from a transection injury is nociceptive neurolysis. In this situation, a patient experiences severe nerve pain with palpation or physical (mechanical) provocation. These patients have pain induced by activity or by certain shoes or braces that trigger the end of the nerve (neuroma). Such patients for whom other therapies have failed are best treated with more proximal transec-

tion and burial because doing so removes the irritated or irritable nerve from the zone of physical stress.

The consistent average improvement of each subset (mechanism of injury, type of procedure) in the current study suggests the authors' empirically derived treatment algorithm assigns the appropriate procedure to a given mechanism of injury. Although only a few patients with chronic intractable lower extremity neuropathic pain had complete relief of symptoms, the results support the hypothesis that improvement is possible for these patients.

References

1. Atweh SF, Kuhar MJ: Autoradiographic localization of opiate receptors in rat brain: I. Spinal cord and lower medulla. *Brain Res* 124:53-67, 1977.
2. Barbera J, Albert-Pamplo R: Centrocenral anastomosis of the proximal nerve stump in the treatment of painful amputation neuromas of major nerves. *J Neurosurg* 79:331-334, 1993.
3. Barbera J, Gonzalez J, Gil JL, et al: The quality and extension of nerve fibre regeneration in the centrocenral anastomosis of the peripheral nerve. *Acta Neurochir Suppl (Wien)* 43:205-209, 1988.
4. Battista A, Cravioto H: Neuroma formation and prevention by fascicle ligation in the rat. *Neurosurgery* 8:191-204, 1981.
5. Battista AF, Lusskin R: The anatomy and physiology of the peripheral nerve. *Foot Ankle* 7:65-70, 1986.
6. Bonica JJ: Regional Anesthesia With Local Anesthetics. In Bonica JJ (ed). *The Management of Pain*. Ed 2. Philadelphia, Lea & Febiger 1883-1996, 1990.
7. Brown H, Flynn JE: Abdominal pedicle flap for hand neuromas and entrapped nerves. *J Bone Joint Surg* 55A:575-579, 1973.
8. Campbell JT, Schon LC, Burkhardt LD: Histopathologic findings in autogenous saphenous vein graft wrapping for recurrent tarsal tunnel syndrome: A case report. *Foot Ankle Int* 19:766-769, 1998.
9. Dellon AL, Aszmann OC: Treatment of superficial and deep peroneal neuromas by resection and translocation of the nerves into the anterolateral compartment. *Foot Ankle Int* 19:300-303, 1998.
10. Dellon AL, MacKinnon SE: Susceptibility of the superficial sensory branch of the radial nerve to form painful neuromas. *J Hand Surg* 9B:42-45, 1984.
11. Devor M, Govrin-Lippmann R, Raber P: Corticosteroids suppress ectopic neural discharge originating in experimental neuromas. *Pain* 22:127-137, 1985.
12. Devor M, Wall PD: Type of sensory nerve fibre sprouting to form a neuroma. *Nature* 262:705-708, 1976.
13. Goldstein SA, Sturim HS: Intraosseous nerve transposition for treatment of painful neuromas. *J Hand Surg* 10A:270-274, 1985.
14. Gorkisch K, Boese-Landgraf J, Vaubel E: Treatment

- and prevention of amputation neuromas in hand surgery. *Plast Reconstr Surg* 73:293-299, 1984.
15. Gould JS: Treatment of the Painful Injured Nerve Continuity. In Gelberman GH (ed). *Operative Nerve Repair and Reconstruction*. Philadelphia, JB Lippincott Co 1541-1550, 1991.
 16. Grant GH: Methods of treatment of neuromata of the hand. *J Bone Joint Surg* 33A:841-848, 1951.
 17. Herndon JH: Neuromas. In Green DP (ed). *Operative Hand Surgery*. New York, Churchill Livingstone 939-955, 1982.
 18. Herndon JH: Neuromas. In Green DP, Hotchkiss RN (eds). *Operative Hand Surgery*. Ed 3. New York, Churchill Livingstone 1387-1400, 1993.
 19. Herndon JH, Eaton RG, Littler JW: Management of painful neuromas in the hand. *J Bone Joint Surg* 58A:369-373, 1976.
 20. Herndon JH, Hess AV: Neuromas. In Gelberman RH (ed). *Operative Nerve Repair and Reconstruction*. Philadelphia, JB Lippincott Co 1525-1540, 1991.
 21. Karev A, Stahl S: Treatment of painful nerve lesions in the palm by "rerouting" of the digital nerve. *J Hand Surg* 11A:539-542, 1986.
 22. Krames ES: Implantable Technologies: When to Use Spinally Administered Opioids or Spinal Cord Stimulation: An Algorithm for Decision-Making. In Campbell JN (ed). *Pain 1996-An Updated Review*. Refresher Course Syllabus. Seattle, International Association of the Study of Pain (IASP Press) 201-206, 1996.
 23. Lidor C, Hall RL, Nunley JA: Centrocetral anastomosis with autologous nerve graft treatment of foot and ankle neuromas. *Foot Ankle Int* 17:85-88, 1996.
 24. Long DM: Electrical stimulation for the control of pain. *Arch Surg* 112:884-888, 1977.
 25. Masear VR, Bonatz E: Painful Neuromas of the Lower Extremity and Postneurectomy Pain. In Omer Jr GE, Spinner M, Van Beek AL (eds). *Management of Peripheral Nerve Problems*. Ed 2. Philadelphia, WB Saunders Co 151-156, 1998.
 26. Masear VR, Tulloss Jr, St. Mary E, et al: Venous wrapping of nerves to prevent scarring. *J Hand Surg* 15A:817-818, 1990. Abstract.
 27. Mass DP, Ciano MC, Tortosa R, et al: Treatment of painful hand neuromas by their transfer into bone. *Plast Reconstr Surg* 74:182-185, 1984.
 28. Max MB, Culnane M, Schafer SC, et al: Amitriptyline relieves diabetic neuropathy pain in patients with normal or depressed mood. *Neurology* 37:589-596, 1987.
 29. McQuay HJ, Carroll D, Glynn CJ: Dose-response for analgesic effect of amitriptyline in chronic pain. *Anaesthesia* 48:281-285, 1993.
 30. Melzack R, Wall PD: Pain mechanisms: A new theory. *Science* 150:971-979, 1965.
 31. Nashold Jr BS, Goldner JL, Bright DS: Direct electrical stimulation of the peripheral nerves for relief of intractable pain. *J Bone Joint Surg* 57A:729, 1975. Abstract.
 32. Otfinowski J, Pawelec A, Kaluza J: Implantation of peripheral neural stump into muscle and its effect on the development of posttraumatic neuroma. *Pol J Pathol* 45:195-202, 1994.
 33. Petropoulos PC, Stefanko S: Experimental observations on the prevention of neuroma formation. *J Surg Res* 1:241-248, 1961.
 34. Robbins TH: Nerve capping in the treatment of troublesome terminal neuromata. *Br J Plast Surg* 39:239-240, 1986.
 35. Schon LC, Clanton TO: Chronic Leg Pain. In Baxter DE (ed). *The Foot and Ankle in Sport*. St Louis, CV Mosby Co 265-283, 1995.
 36. Schon LC, Easley ME: Chronic Pain. In Myerson MS (ed). *Foot and Ankle Disorders*. Philadelphia, WB Saunders Co 851-881, 2000.
 37. Schon LC, Easley ME, Anderson CA, et al: Management of severe intractable lower extremity nerve pain with peripheral nerve vein wrapping or peripheral nerve stimulation. *Foot Ankle Int* 20:670, 1999. Abstract.
 38. Shealy CN, Mortimer JT, Reswick JB: Electrical inhibition of pain by stimulation of the dorsal columns: Preliminary clinical report. *Anesth Analg* 46:489-491, 1967.
 39. Skalley TC, Schon LC, Hinton RY, et al: Clinical results following revision tibial nerve release. *Foot Ankle Int* 15:360-367, 1994.
 40. Smith JR, Gomez NH: Local injection therapy of neuromata of the hand with triamcinolone acetate: A preliminary study of twenty-two patients. *J Bone Joint Surg* 52A:71-83, 1970.
 41. Sotereanos DG, Giannakopoulos PN, Mitsionis GI, et al: Vein-graft wrapping for the treatment of recurrent compression of the median nerve. *Microsurgery* 16:752-756, 1995.
 42. Spiegel K, Kalb R, Pasternak GW: Analgesic activity of tricyclic antidepressants. *Ann Neurol* 13:462-465, 1983.
 43. Sunderland S: *Nerves and Nerve Injuries*. Ed 2. New York, Churchill Livingstone 1978.
 44. Tupper JW, Booth DM: Treatment of painful neuromas of sensory nerves in the hand: A comparison of traditional and newer methods. *J Hand Surg* 1A:144-151, 1976.
 45. Wall PD, Sweet WH: Temporary abolition of pain in man. *Science* 155:108-109, 1967.
 46. Watson CP, Evans RJ, Reed K, et al: Amitriptyline versus placebo in postherpetic neuralgia. *Neurology* 32:671-673, 1982.
 47. Whipple RR, Unsell RS: Treatment of painful neuromas. *Orthop Clin North Am* 19:175-185, 1988.
 48. White JC, Sweet WH: *Pain and the Neurosurgeon: A Forty-Year Experience*. Springfield IL, Charles C Thomas 1969.
 49. Wilbourn AJ, Shields Jr RW: Generalized Polyneuropathies and Other Nonsurgical Peripheral Nervous System Disorders. In Omer Jr GE, Spinner M, Van Beek AL (eds). *Management of Peripheral Nerve Problems*. Ed 2. Philadelphia, WB Saunders Co 648-660, 1998.
 50. Williams HB: The painful stump neuroma and its treatment. *Clin Plast Surg* 11:79-84, 1984.