

Metatarsalgia: Distal Metatarsal Osteotomies

Reinhard Schuh, MD^{a,*}, Hans Joerg Trnka, MD^b

KEYWORDS

- Chevron osteotomy • Closing wedge osteotomy
- Metatarsalgia • Metatarsophalangeal joints • Weil osteotomy

Metatarsalgia is among the most common sources of pain in the human body. Some use the term broadly to refer to a number of painful conditions in the forefoot. However, metatarsalgia has been differentiated from other forefoot conditions and is defined as pain across the plantar forefoot beneath the second, third, and fourth metatarsal heads. The many causes of metatarsalgia can be categorized in 3 groups: (1) Local disease in the region (eg, interdigital neuroma), (2) altered forefoot biomechanics (clawtoe, hallux rigidus), and (3) systemic disease affecting the region (rheumatoid arthritis).¹

For all causes, the first-line treatment is nonoperative therapy. This includes shoe modification (stiff sole, retrocapital metatarsal bar), custom foot orthoses with a metatarsal pad, and gastrosoleus stretching exercises. Additionally, corticosteroid injections as well as shaving of callosities can be carried out. However, if nonoperative treatment fails, operative options are considered.

PATHOBIOMECHANICS

To understand pathobiomechanic mechanisms causing metatarsalgia, the basic principles of the gait cycle have to be understood. The cycle is divided into two phases: Stance phase (60% of the normal gait cycle) and swing phase (40% of the normal cycle). The forefoot is in contact with the ground throughout approximately half of the gait cycle. In normal stance, the metatarsal heads all should rest evenly on the floor. The first, fourth, and fifth metatarsals are mobile in the sagittal plane. The second and third metatarsals are relatively fixed in position by rigid articulations with their corresponding cuneiforms.¹ During walking, the foot functions as a 3-rocker mechanism, providing physiologic balance between forward movement of the body and stability of the foot and leg during the stance phase.²⁻⁴

The heel represents the first rocker, beginning with heel strike during the first 10% of the gait cycle. Metatarsalgia that is present in this particular phase of gait is usually

The authors have nothing to disclose.

^a Department of Orthopaedics, Vienna General Hospital, Medical University of Vienna, Waehringer Guertel 18-20, Vienna 1180, Austria

^b Foot and Ankle Center Vienna, Alserstrasse 43/8D, Vienna 1080, Austria

* Corresponding author.

E-mail address: reinhard.schuh@meduniwien.ac.at

Foot Ankle Clin N Am 16 (2011) 583–595

doi:10.1016/j.fcl.2011.08.009

1083-7515/11/\$ – see front matter © 2011 Elsevier Inc. All rights reserved.

foot.theclinics.com

caused by congenital deformities, for example, cavus foot or tight gastrosoleus complex. A cavus foot has an abnormal increase in longitudinal arch, which places weight bearing on the heel and metatarsal heads, with little or no support from the lateral plantar midfoot. The toes commonly remain in extension at the metatarsophalangeal (MTP) joint with the greater flexion angles of the corresponding metatarsals. Weight-bearing pressure is concentrated under the metatarsal heads as a result of the abnormal foot position. Forefoot varus increases the amount of weight bearing on the lateral aspect of the foot and leads to increased pressures under the fifth metatarsal head. In similar manner, forefoot valgus increases pressure under first the metatarsal head.¹

The ankle is the second rocker during the next 20% of gait. In this phase (flat foot), the entire foot contacts the ground. Forefoot overloading occurs in this phase if ankle range of motion is restricted and if the plantarflexion of the metatarsals is increased.⁵ The pressure transfers rapidly toward the forefoot after heel strike. During toe off, pressure moves rapidly toward the digits, primarily to the great toe. The first ray (first metatarsal or great toe) participates in 50% of weight bearing, the lesser rays contribute the other 50% (**Fig. 1**).

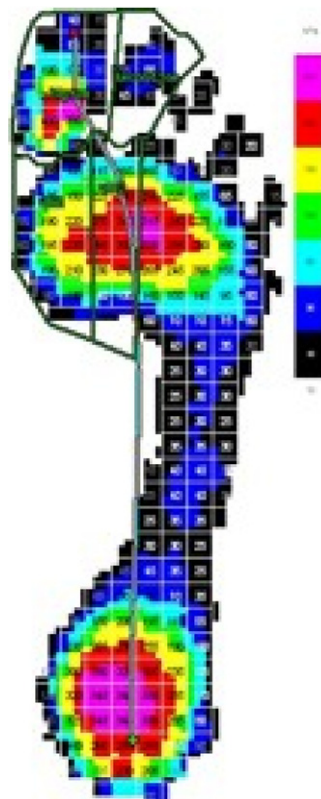


Fig. 1. Physiologic plantar pressure distribution during the stance phase of gait. During toe-off, the pressure moves rapidly to the great toe. This is shown by the deviation of the line that indicates the center of pressure in the forefoot area. The hallux is the major weight-bearing structure of the forefoot during stance phase of gait.

During the third rocker (toe off), only the forefoot is in contact with the ground and the MTP joints are dorsiflexed. Therefore, deformities of the MTP joints can produce metatarsalgia. Additionally, pathologic conditions on one metatarsal can cause overload of its neighbors. Hallux valgus alters first ray mechanics interrupting the windlass mechanism and weakening great toe flexion, which causes metatarsalgia (**Fig. 2**). Hallux rigidus, first ray hypermobility and iatrogenic weakening of the first MTP joint are common causes of metatarsalgia.⁵

CLINICAL EVALUATION

Evaluation of the patient starts with a careful history and physical examination.⁶ A thorough patient history is taken and the foot is evaluated in weight-bearing and non-weight-bearing positions. History is focused on localizing pain, onset of symptoms, and alleviating or aggravating factors. The magnitude of deformity and the

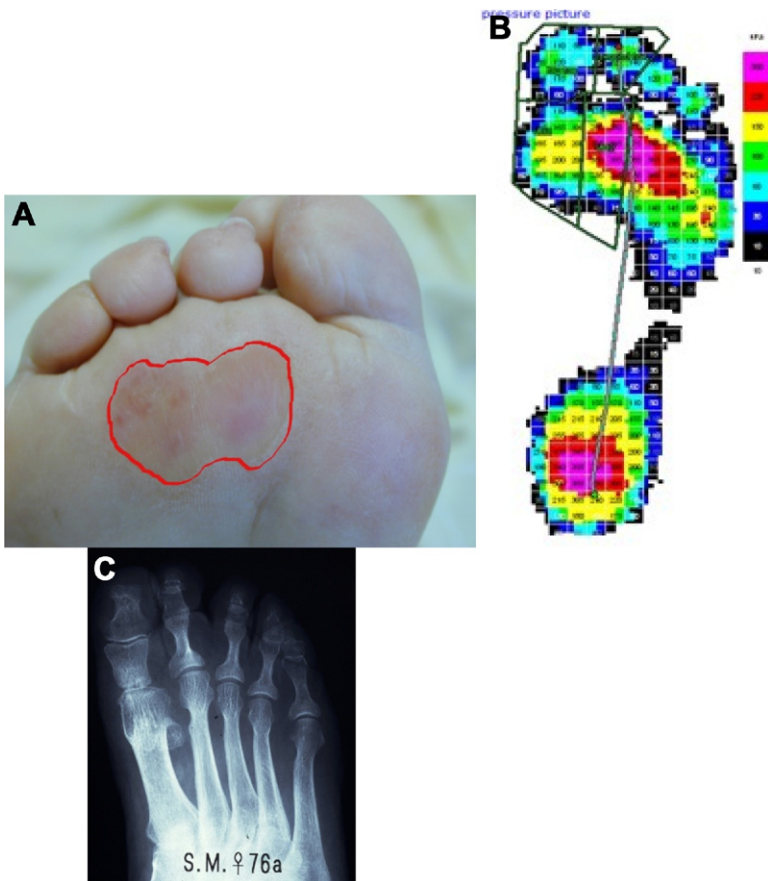


Fig. 2. (A) Foot of a patient with third rocker keratosis at the MTP 2 to 4 region owing to first ray insufficiency after Keller-Brandes resectional arthroplasty of the first MTP joint. (B) Plantar pressure analysis of the same patient. The pink and red areas indicate central overload. There is a lateralization of the center of pressure owing to first ray insufficiency and almost no weight bearing of the first ray. (C) Corresponding dorsoplantar x-ray.

effect of shoe wear on the foot are identified. It is important to note skin changes and deformities such as clawtoes, hammer toes, and hallux valgus, which can contribute to increased pressure under the metatarsal heads.

Assessing plantar calluses may give clues as to the pathology involved. Second rocker keratosis is strictly plantar under the metatarsal head. The foot should be evaluated for abnormal plantarflexion of the lesser metatarsals. Other causes of second rocker keratosis include gastrosoleus contracture and pes cavus. These keratoses do not show a tendency to extend distally toward the toes.

In contrast, third rocker keratosis is found more distal under the affected heads (see **Fig. 2A**). Each keratosis may be diffuse and span several heads. Keratosis associated with first ray insufficiency (ie, hallux valgus, hallux rigidus) exhibit third rocker features.⁵

After inspection, the foot is palpated and functional evaluation is performed. Palpation begins systematically, from the front to the rear. The goals of palpation are the assessment of topographic anatomy and recognition of any deviations. All bony prominences, anatomic regions, and metatarsals should be palpated. The plantar aspect of the foot along with each digit must be examined for the development of callosities and MTP alignment.⁶ Each intermetatarsal web space is palpated to assess for tenderness of the interdigital nerves.⁵

Stability of the MTP joints in the sagittal and transversal plane must be tested. The examiner stabilizes the metatarsal neck in 1 hand and attempts to displace the base of the proximal phalanx with the other hand while holding the joint in the neutral position (toe Lachman test).

Hypermobility of the first ray and restricted dorsiflexion at the first MTP joint should be noted as well as hallux rigidus.⁷ In addition, inversion and eversion range of motion of the hindfoot as well as medial columns stability should be evaluated.⁵

All muscles should be checked to assess strength and function. The Silfverskiöd method is used to evaluate for contracture of the gastrosoleus complex. Ankle dorsiflexion is tested with the knee in full extension and in 90° of flexion; the foot is maintained in an inverted position to avoid dorsiflexion movements at the midtarsal joints. Increased ankle dorsiflexion with the knee flexed indicates contracture of the gastrocnemius muscles.⁵

To provide a biomechanically objective investigation, dynamic plantar pressure distribution analysis can be performed. This reveals a reproducible image of plantar load distribution and may contribute to the therapeutic algorithm.

Radiographic Evaluation

Standard dorsoplantar and lateral weight-bearing radiographic views are obtained to evaluate the whole foot. The dorsoplantar view helps to identify MTP joint congruency, arthritis, and metatarsal length, as well as the degree of hindfoot deformity accompanying the forefoot deformity. There is typically a clear space of 2 to 3 mm between the metatarsal and adjacent phalanx. As the MTP hyperextends, the clear space diminishes and the phalanx subluxes dorsally over the metatarsal head. This is demonstrated on an anteroposterior radiograph as a diminished clear space and an overlapping adjacent bone.⁸ If metatarsus primus varus is present, hallux valgus angle and intermetatarsal angle can be assessed as well on dorsoplantar views. In a radiographic study, Maestro and co-workers⁹ introduced measures to assess forefoot geometry in detail on the dorsoplantar view. The lateral view can show collapse of the medial longitudinal arch and depict the magnitude of MTP joint dislocation to preoperatively gauge shortening.

Bone scans and magnetic resonance imaging can be helpful adjuncts in the inspection of neoplasm and infection, whereas computed tomographic scans can

depict complex traumatic injuries. Neither is typically necessary in the management of metatarsalgia, however. Ultimately, imaging should support the clinical examinations and the decision for operative intervention.⁶

Preoperative Planning

Preoperative planning plays a crucial role in assessing the feasibility of an individual procedure and optimizing clinical outcomes. An accurate differential diagnosis, extensive understanding of disease pathophysiology, and knowledge of associated symptoms enables the surgeon to properly identify the lesions amenable for operative correction.

The 3-rocker assessment of gait helps to determine the necessary procedure. First rocker pathologies are usually caused by complex hindfoot deformities, and a simple distal metatarsal osteotomy is insufficient. In this situation, the underlying cause needs to be addressed, such as correction of the cavo varus deformity or an Achilles tendon lengthening. Second rocker gait pathologies are caused by decreased dorsiflexion of the ankle joint or plantarflexed metatarsals. This can be either corrected operatively to increase the ankle dorsiflexion or with a proximal metatarsal elevation osteotomy. Classical indications for distal metatarsal osteotomies are third rocker of gait pathologies like MTP subluxations or dislocations, crossover toe deformities, or relative overlength of the lesser metatarsal, whether congenital or acquired. One must be thorough in evaluating the entire lower extremity because global foot deformities can influence outcomes when addressing forefoot pathology.⁶

Lauf and Weinraub¹⁰ used lateral x-rays to estimate the symptomatic metatarsal declination angle (β) and the clinically determined amount of metatarsal head elevation (Δh). A trigonometric formula, $\Delta h = X (\sin \beta)$, where X is the unknown amount of bone that needs to be resected to yield the desired elevation, can theoretically be used intraoperatively to measure shortening.¹⁰ Although this is certainly an important theoretical consideration, it is cumbersome for usage in clinical work. In the operating room, the authors usually determine the necessary amount of shortening on the preoperative standing radiographs. For a single shortening, the adjacent lesser metatarsal head is palpated and the proximal translation of the osteotomy is performed to equalize this length difference. The standard thickness of wedge resection is usually 3 mm (1 mm bone slice plus 1 mm each for the saw blade thickness).

Operative Techniques

The goal of the operation is to improve plantar pressure distribution within the forefoot after failure of nonoperative treatment. Lesser metatarsal osteotomy is an effective and well-accepted method for the management of metatarsalgia. The main purpose of these osteotomies is to decrease prominence of the symptomatic metatarsal head. This can be done by dorsiflexing the metatarsal head, shortening the metatarsal head, or some combination thereof. Accurate correction is important because insufficient shortening or elevation leads to recurrent metatarsalgia, whereas overzealous correction results in transfer lesions to the adjacent metatarsals. Depending on the underlying pathology, the surgeon must decide whether it is necessary to address metatarsalgia with lesser metatarsal osteotomy only or if additional procedures, such as Achilles tendon lengthening, flexor-to-extensor tendon transfer or repair of the plantar plate are necessary.^{1,5}

All techniques can be performed under a regional ankle block with an Esmarch bandage as a tourniquet if needed. The senior author prefers forefoot surgery without tourniquet, which helps to limit postoperative swelling and edema.

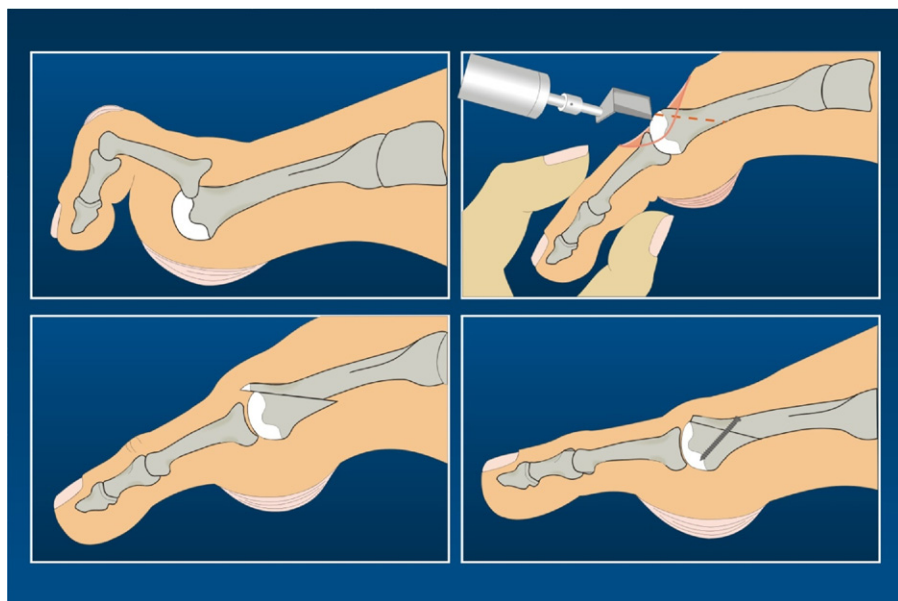


Fig. 3. Major steps of the Weil osteotomy in case of a dislocated MTP joint.

Distal Oblique Metatarsal Osteotomy (Weil Osteotomy)

The Weil osteotomy was first described by in 1985 for the treatment of central metatarsalgia. In 1992, it was introduced in France by Barouk.^{11,12} The goal of a Weil osteotomy is to achieve adequate proximal translation of the metatarsal head in relation to the callus and to more evenly distribute pressure underneath the forefoot with adequate metatarsal–ground contact during third rocker. It is an intra-articular osteotomy that achieves longitudinal decompression through shortening.⁵ A schematic drawing of the principles of this osteotomy is presented in Fig. 3.

A dorsal, 3-cm, longitudinal incision is made over the metatarsal for a single osteotomy and over the web space for adjacent osteotomies. In most cases, a z-type lengthening of the short and long extensor tendons is performed. After identifying the metatarsal head and neck, the joint capsule is incised. A laminar spreader is now inserted to expose the metatarsal. The laminar spreader is the instrument of choice since when using Hohmann retractors the saw blade will be blocked by the retractors. The collateral ligaments of the MTP joint are cut, the dislocation of the MTP joint is partly reduced, and the toe is flexed to give optimal exposure of the metatarsal head. According to the original technique by Barouck, the plane of the osteotomy is parallel to the ground as if the foot was bearing weight.

Cadaveric studies have shown that, in clinical use, this is almost impossible and it has led to recurrent metatarsalgia. With our technique, we routinely resect a bony wedge of 3 to 4 mm to avoid plantar displacement with the proximal translation. After removal of the free bony slice, the plantar mobile fragment is then grasped with a pointed clamp and shifted proximally to achieve the requisite amount of shortening. After checking the positioning with the image intensifier, the two fragments are secured with a special titanium snap-off screw or a solid cortical lag screw. We recommend the 2-mm twist-off screw (Wright Medical, Arlington, TN, USA) rather than standard cortical lag screws or Kirschner wires for fixation of the Weil osteotomy. Most of

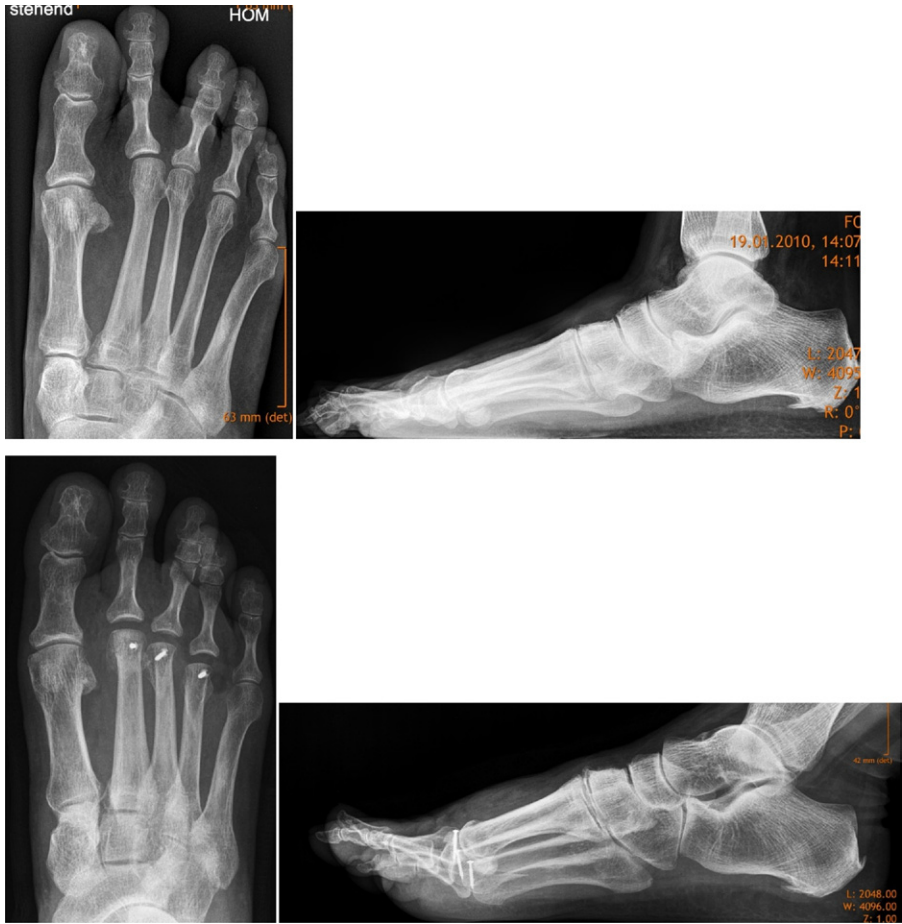

Fig. 4. Preoperative and postoperative dorsoplantar and lateral radiographs of a patient with third rocker metatarsalgia owing to a relatively short first ray and crossover toe deformity of the second toe. The patient underwent Weil osteotomy of the second, third, and fourth metatarsal heads. The clear space of the MTP joint is increased postoperatively, which indicates decompression of the joints.

the available minifragment screws require predrilling, which may displace the plantar fragment. The twist-off screw is used without predrilling and offers acceptable fixation in most cases. The resulting dorsal protuberance on the metatarsal head is then resected.¹³ Weight bearing in a postoperative shoe is allowed immediately after surgery.¹⁴

Fig. 4 shows the dorsoplantar and lateral x-ray of a patient with third rocker metatarsalgia owing to a relatively short first ray and cross over toe deformity of the second toe. The patient underwent Weil osteotomy of the second, third, and fourth metatarsal heads.

Good to excellent results have been reported in 70% to 100% of patients treated with conventional Weil osteotomy.^{13,15–18} Postoperative complications include MTP joint stiffness, floating-toe deformity, local second rocker metatarsalgia resulting from plantar shift of the lesser metatarsal head, transfer metatarsalgia caused by extensive

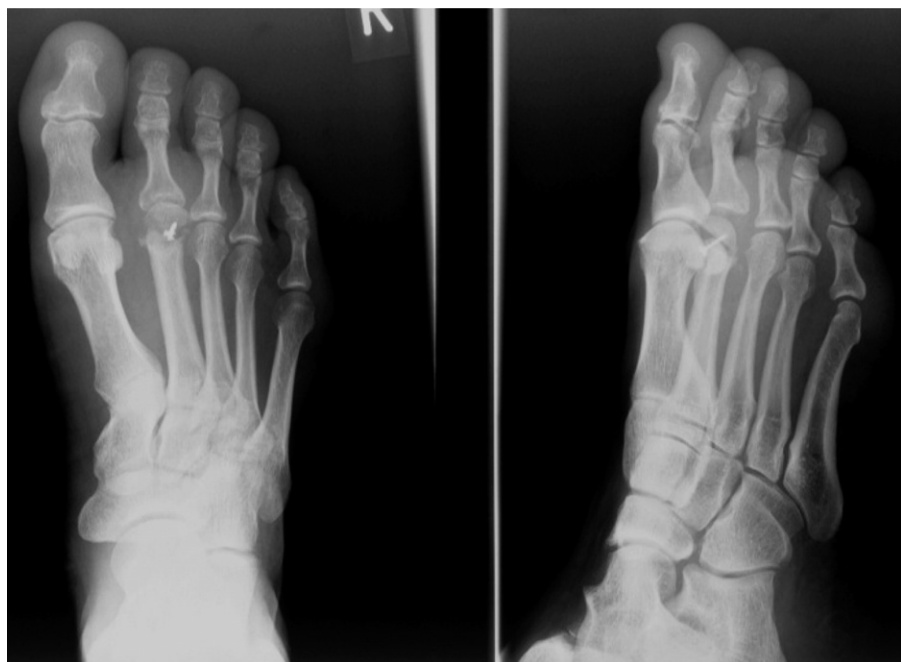

Fig. 5. Radiograph 6 months after Weil osteotomy of the second metatarsal. Nonunion occurred.

shortening, nonunion (**Fig. 5**), superficial wound healing problems, and complex regional pain syndrome.⁵ The floating toe and MTP joint stiffness are the most common postoperative complications. One reason is the dorsal approach to the joint capsule, which may lead to postoperative contracture and cocking up of the toe. Another reason may be insufficiency of the plantar plate, which can lead to dorsal subluxation of the MTP joint and a floating toe. Our solution is lengthening of the extensor tendons and, if possible, a reconstruction of the plantar plate by transosseous sutures of the distal plantar plate through the base of the proximal phalanx. In some obvious cases of dorsal dislocation intraoperatively, we pass a 1.4-mm K-wire from the toe through the metatarsal head across the osteotomy into the proximal metatarsal shaft. Postoperative taping of the toes may also help to avoid subsequent cocking up of the toe.

In a cadaveric study, our group investigated biomechanical changes of the interosseous muscles after performing conventional Weil osteotomy in 4 different angles in relation to the longitudinal axis of the metatarsal (25° – 40°). We found that the tendons of the interosseous muscles moved dorsally in relation to the MTP joint owing to depression of the plantar fragment of the metatarsal. This leads to loss of their flexion moment on the MTP joint. Therefore, the pull of the extensor leads to dorsiflexion of the toe and the interosseous muscles act as a synergist for dorsiflexion of the MTP joint. The amount of depression ranged from 3.0 to 4.6 mm, depending on the angle of the osteotomy. We concluded that the investigated biomechanical changes may explain the commonly seen dorsiflexion contracture after Weil osteotomy. Based on the results of this cadaveric study, the following modifications were recommended: (1) Lengthening of the extensor tendon(s), (2) making the osteotomy

plane as parallel as possible to the ground surface, (3) adding a flexor to extensor transfer, and (4) inserting a Kirschner wire from the tip of the toe across the MTP joint and the osteotomy into the MTP joint (in a position of 5° of plantar flexion). The Kirschner wire prevents dorsiflexion during soft tissue healing, but intensive physiotherapy after 4 weeks is necessary to prevent stiffness of the joint.¹⁹ Because flexor to extensor tendon transfer leads to bulky dorsal soft tissue and increases the likelihood of wound healing problems, we have abandoned this procedure.

To avoid complications associated with the traditional Weil osteotomy, Maceira and colleagues²⁰ introduced a 3-step modification of the Weil osteotomy. This modification aims to recreate a more anatomic metatarsal, with preservation of the relative length and position of the interossei musculature in relation to the center of rotation of the MTP joint. In addition, the shape and integrity of the cartilage of the metatarsal head are not altered. The direction of shortening of the conventional Weil osteotomy runs mostly parallel to the plantar aspect of the foot, whereas in the triple Weil osteotomy it is coaxial to the bone. Espinosa and co-workers⁵ reported low rates of MTP joint stiffness and floating toe deformity with the 3-step technique. Potential complications include osteonecrosis of the metatarsal head, infection, synostosis, plantar migration of the hardware, and neurovascular impairment.⁵

Benichou performed another extra-articular modification of the conventional Weil osteotomy by doing a step cut keeping the plantar cortex of the distal fragment.¹²

If the MTP joint is not affected (no subluxation or dislocation) in case of crossover toe deformity or isolated overlength of the metatarsal, the authors perform the Weil osteotomy in an extra-articular fashion by starting the cut at the metadiaphyseal junction of the distal metatarsal region.

Vandeputte and associates¹⁷ evaluated plantar pressure distribution in addition to clinical results after Weil osteotomy. The investigations have been performed pre- and postoperatively. They noted a reduction of plantar pressure under the operated metatarsal head in all but 1 patient. The mean decrease was 1.0 kg/cm². The decrease in pressure corresponded to a good clinical result and showed a correlation between pressure reduction and patient outcome.¹⁷

Recently, minimally invasive modifications of Weil osteotomy have been introduced.²¹ However, there is no evaluation of such methods in the peer-reviewed literature to date.

Author's Preferred Technique for the Modified Weil Osteotomy

The senior author prefers a modified Weil osteotomy in the majority of cases. The key step in this modification that differs from the originally described technique includes the removal of a slice of bone at the osteotomy site. Theoretically, this improves the plantar pressure relief in the forefoot region; however, this has not been definitively proven biomechanically.

The surgery is performed using a regional ankle block for anesthesia, and supplement with intravenous or oral sedation. An Esmarch-tourniquet may be used to obtain a bloodless field. A 3-cm, longitudinal incision is made dorsal over the metatarsal for a single osteotomy, over the web space for a double osteotomy. A small amount of soft tissue dissection is done to identify the extensor tendons, which is lengthened in a Z-fashion. A transverse or longitudinal capsulotomy of the MTP joint is made to identify the junction of the head and neck. The metatarsal head is exposed with a laminar spreader. Care is taken not to strip the plantar soft tissue attachments to aid in stabilizing the osteotomy and maintain vascularity to the head.²² The dislocation of the MTP joint is partly reduced and the toe is flexed plantar to give optimal exposure of the metatarsal head. After that, a 1- to 2-mm bony slice

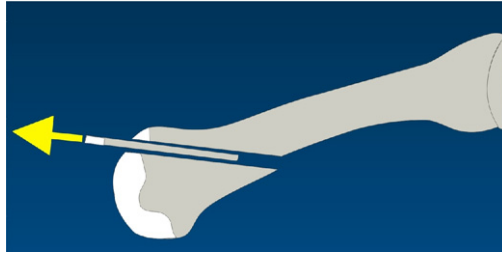

Fig. 6. Removal of the bony slice to achieve elevation of the metatarsal head.

extraction is desired to lift the dorsal fragment because the axis of motion of the MTP joint has changed with plantar flexion of the metatarsal head (**Figs. 6 and 7**). In this abnormal case, the interosseous muscle act as dorsiflexor rather than plantarflexor and result in a contracted subluxated MTP joint.¹⁹ Using an oscillating saw, the osteotomy aims from the dorsal portion of the metatarsal head proximally. The second osteotomy through both cortices is 2 mm under the dorsal cut. The bony slice can now be easily removed.

The plantar mobile fragment is then grasped with a pointed reduction clamp and is shifted proximally to achieve the requisite amount of shortening that was measured preoperatively on the dorsoplantar radiographs. The plane of the osteotomy has to be as parallel to the ground surface as possible. The osteotomy was secured with a special 2 mm titanium “Twist off screw” (Wright Medical). We have abandoned the K-wires for fixation of the Weil osteotomy and recommend the “twist-off” screw for fixation of the osteotomy. Most of the available minifragment screws require predrilling, which may dislocate the plantar fragment. The so-called twist-off screw is used without predrilling. The resulting dorsal protuberance over the metatarsal head remnant was removed with a rongeur. Finally the overlying Z-lengthened extensor tendon is repaired and the skin sutured.

Although the classical Weil osteotomy is an intra-articular procedure indicated for sagittal plane MTP dislocation, horizontal plane pathologies like crossover toe

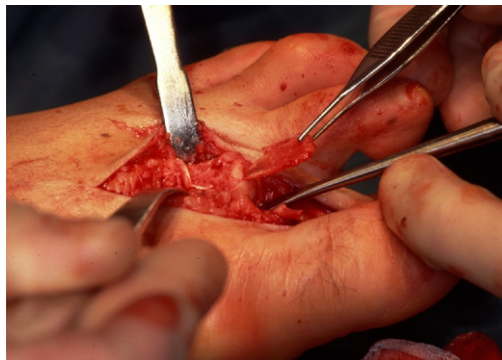

Fig. 7. Intraoperative situation after double osteotomy and removal of the bony slice in a patient who underwent modified Weil osteotomy of the second metatarsal for the treatment of metatarsalgia caused by subluxation of the second MTP joint (third rocker of gait metatarsalgia).

deformities might benefit from maintaining the dorsal joint. In these cases, an extra-articular Weil osteotomy with wedge resection is performed. The difference to the classic Weil osteotomy is that this osteotomy is performed proximal to the joint capsule. Adequate elevation can be achieved by resection of a bony slice. Shortening and decompression of the MTP joint pressure can be achieved by pushing the plantar fragment proximally, with standard 2.0-mm cortical screws used for fixation.

Distal Metatarsal V (Closing Wedge) Osteotomy

Leventen and Pearson first described this type of osteotomy as a modification of the method described by Wolf.^{23–25} It represents a V-shaped osteotomy with a plantar apex. It is carried out in the metadiaphyseal junction of the metatarsal. Wolf originally determined the diaphysis of the metatarsal as location of the osteotomy and recommended to perform it at 1 metatarsal at each stage.²⁵ To avoid transfer lesions, Leventen and Pearson followed a set protocol. If the hyperkeratosis was located under the second metatarsal head only, the second and third metatarsal heads were addressed surgically. If the hyperkeratosis was under the fourth metatarsal head, osteotomies of the third and fourth metatarsal were performed. If hyperkeratosis was present underneath the third metatarsal head, osteotomies of the second to fourth metatarsal were carried out.

After the MTP joint is approached in usual manner, a V-shaped trough is made in the dorsal three fourths of the metatarsal neck using a rongeur. This trough is 5 mm at its widest point. The osteotomy is closed using manual pressure. No fixation is used. Patients are encouraged to weight bear to keep the osteotomy closed 24 hours after the procedure.

Leventen and Pearson reported in 1987 in 21 feet a decrease of subjective pain score from 7.7 to 1.3. Five patients continued to have metatarsalgia, one of them worsened postoperatively. Sixteen patients were completely satisfied, two were satisfied, and three were dissatisfied.²³ We have no personal experience performing this technique, and it seems to be more of historical interest.

Chevron Osteotomy

Kitaoka and Platzer²⁶ described a distal chevron osteotomy for the treatment of metatarsalgia. The apex of the cut was centered at the metadiaphyseal junction of the metatarsal. The limbs of the osteotomy were at 45° directed proximally and the cut made vertically relative to the metatarsal. The distal fragment was displaced dorsally approximately 2 to 3 mm and manually impacted. The authors believed the osteotomy was stable, but used internal fixation with a short threaded Kirschner wire.

In their series, they reported pain relief in 15 of a total of 19 patients. Two patients required revision surgery owing to severe residual pain. Three patients suffered transfer metatarsalgia. The mean amount of shortening with this osteotomy was 2.6 mm. With the dorsally directed force of weight bearing in line with the osteotomy, however, excess dorsal displacement is possible without internal fixation. When performing this osteotomy, it is wise to use internal fixation. If fixation is not performed, there may be increased risk of transfer metatarsalgia.

SUMMARY

Metatarsalgia is a common pathologic entity. It refers to pain at the MTP joints. Pain in the foot unrelated to the MTP joints (such as Morton's neuroma) must be distinguished from those disorders, which lead to abnormal pressure distribution, reactive calluses, and pain.

Initial treatment options for metatarsalgia include modifications of shoe wear, metatarsal pads, and custom-made orthoses. If conservative treatment fails, operative reconstructive procedures in terms of metatarsal osteotomies should be considered. Lesser metatarsal osteotomy is an effective and well-accepted method for the management of metatarsalgia. The main purpose of these osteotomies is to decrease prominence of the symptomatic metatarsal head. The distal metatarsal oblique osteotomy (Weil osteotomy) with its modification represents the best evaluated distal metatarsal osteotomy in terms of outcome studies and biomechanical analysis. The role of the Weil osteotomy in metatarsalgia owing to a subluxed or dislocated MTP joint is to bring the metatarsal head proximal to the callus and to provide axial decompression of the toe to correct the deformity contributing to metatarsalgia.

REFERENCES

1. Feibel JB, Tisdell CL, Donley BG. Lesser metatarsal osteotomies. A biomechanical approach to metatarsalgia. *Foot Ankle Clin* 2001;6:473–89.
2. Perry J. *Gait analysis: Normal and pathologic function*. Thorofare (NJ): Slack Inc.; 1992.
3. Daniels T, Thomas R. Etiology and biomechanics of ankle arthritis. *Foot Ankle Clin* 2008;13(3):341–52.
4. Bober T, Dziuba A, Kobel-Buys K, et al. Gait characteristics following Achilles tendon elongation: the foot rocker perspective. *Acta Bioeng Biomech* 2008;10:37–42.
5. Espinosa N, Brodsky JW, Maceira E. Metatarsalgia. *J Am Acad Orthop Surg* 2010;18:474–85.
6. Hamilton KD, Anderson JG, Bohay DR. Current concepts in metatarsal osteotomies: a remedy for metatarsalgia. *Techniques in Foot & Ankle Surgery* 2009;8:77–84.
7. Grebing BR, Coughlin MJ. The effect of ankle position on the exam for first ray mobility. *Foot Ankle Int* 2004;25:467–75.
8. Davis H, Mann R. Principles of the physical examination of the foot and ankle. In: Coughlin M, Mann R, Saltzmann C, editors. *Surgery of the foot and ankle*. Philadelphia: Mosby, Elsevier; 2007. p. 45–70.
9. Maestro M, Besse JL, Ragusa M, et al. Forefoot morphotype study and planning method for forefoot osteotomy. *Foot Ankle Clin* 2003;8:695–710.
10. Lauf E, Weinraub GM. Asymmetric “V” osteotomy: a predictable surgical approach for chronic central metatarsalgia. *J Foot Ankle Surg* 1996;35:550–9.
11. Viladot A. To Weil or not to Weil. Abstractbook of the 8th International Congress of the European Foot and Ankle Society. Geneva, 2010.
12. Maestro M. Weil: YES! Why? Abstractbook of the 8th International Congress of the European Foot and Ankle Society. Geneva, 2010.
13. Hofstaetter SG, Hofstaetter JG, Petroustas JA, et al. The Weil osteotomy: a seven-year follow-up. *J Bone Joint Surg Br* 2005;87:1507–11.
14. Schuh R, Trnka HJ, Sabo A, et al. Biomechanics of postoperative shoes: plantar pressure distribution, wearing characteristics and design criteria: a preliminary study. *Arch Orthop Trauma Surg* 2010;131:197–203.
15. Trnka HJ, Gebhard C, Muhlbauer M, et al. The Weil osteotomy for treatment of dislocated lesser metatarsophalangeal joints: good outcome in 21 patients with 42 osteotomies. *Acta Orthop Scand* 2002;73:190–4.
16. Hart R, Janecek M, Bucek P. The Weil osteotomy in metatarsalgia. *Z Orthop Ihre Grenzgeb* 2003;141:590–4.
17. Vandeputte G, Dereymaeker G, Steenwerckx A, et al. The Weil osteotomy of the lesser metatarsals: a clinical and pedobarographic follow-up study. *Foot Ankle Int* 2000;21:370–4.

18. Jarde O, Hussenot D, Vimont E, et al. Weil's cervicocapital osteotomy for median metatarsalgia: report of 70 cases. *Acta Orthop Belg* 2001;67:139–48.
19. Trnka HJ, Nyska M, Parks B, et al. Dorsiflexion contracture after the Weil osteotomy: results of cadaver study and three-dimensional analysis. *Foot Ankle Int* 2001;22:47–50.
20. Maceira E, Farinas F, Tena J, et al. Analysis of metatarsophalangeal stiffness following Weil osteotomies. *Rev Med Cir Pie* 1998;12:35–40.
21. De Prado M. Principles of percutaneous and MIS. Abstractbook of the 8th International Congress of the European Foot and Ankle Society. Geneva, 2010.
22. Sammarco G, Scioli MW. Metatarsal osteotomy using a double threaded compression screw. *Foot Ankle Int* 1989;10:129–39.
23. Wolf M. Metatarsal osteotomy for the relief of painful metatarsal callosities. *J Bone Joint Surg Am* 1973;55:1760–2.
24. Kitaoka H, Platzer GL. Chevron osteotomy of lesser metatarsals for intractable plantar callosities. *J Bone Joint Surg Br* 1998;80:516–8.
25. Petersen WJ, Lankes JM, Paulsen F, et al. The arterial supply of the lesser metatarsal heads: a vascular injection study in human cadavers. *Foot Ankle Int* 2002;23:491–5.
26. Leventen E, Pearson SW. Distal metatarsal osteotomy for intractable plantar keratosis. *Foot Ankle Int* 1987;10:274–51.