Intermediate-Term Results of the Ludloff Osteotomy in One Hundred and Eleven Feet

By H.-J. Trnka, MD, S.G. Hofstaetter, MD, J.G. Hofstaetter, MD, F. Gruber, MD, S.B. Adams Jr., MD, and M.E. Easley, MD

Investigation performed at the Orthopaedic Hospital Gersthof, Vienna, Austria, and the Duke University Foot and Ankle Service, Raleigh, North Carolina

Background: The modified Ludloff proximal first metatarsal osteotomy is indicated for the surgical correction of moderate-to-severe hallux valgus deformity associated with metatarsus primus varus. We report the intermediate-term results of this procedure.

Methods: Ninety-nine patients (111 feet) with a mean age of fifty-six years underwent a modified Ludloff proximal first metatarsal osteotomy and a distal soft-tissue procedure at two institutions for the treatment of a moderate-to-severe hallux valgus deformity. The American Orthopaedic Foot and Ankle Society score and weight-bearing radiographs of the foot were assessed preoperatively and after a mean duration of follow-up of thirty-four months. Clinical and radiographic outcome was also compared between younger and older patients, with the arbitrarily chosen age of sixty years dividing the two groups.

Results: The mean American Orthopaedic Foot and Ankle Society score improved significantly ($p < 0.0001$) from 53 points preoperatively to 88 points at the time of the most recent follow-up. The mean American Orthopaedic Foot and Ankle Society score for patients who were sixty years of age or less was significantly higher than that for patients who were more than sixty years of age (91 compared with 83 points; $p = 0.0057$). The mean hallux valgus angle decreased significantly from 35° preoperatively to 9° at the time of the most recent follow-up ($p < 0.0001$), and the mean intermetatarsal angle decreased significantly from 17° to 8° ($p < 0.0001$). All osteotomy sites united without dorsiflexion malunion but with a mean first metatarsal shortening of 2.2 mm.

Conclusions: To our knowledge, the present report describes the largest cohort of patients undergoing a modified Ludloff osteotomy for the correction of hallux valgus deformity that has been reported in the literature. Our intermediate-term results demonstrate that the procedure achieves significant correction of moderate-to-severe hallux valgus deformity, significant reduction in forefoot pain, and significant improvement in functional outcome. Patients with an age of sixty years or less appear to have a more favorable outcome.

Level of Evidence: Therapeutic Level IV. See Instructions to Authors for a complete description of levels of evidence.

Symptomatic hallux valgus associated with a first intermetatarsal angle of ≥15° is typically corrected with a proximal first metatarsal osteotomy combined with a distal soft-tissue procedure when nonoperative treatment fails[1,2]. While the crescentic proximal first metatarsal osteotomy has been associated with acceptable clinical outcomes[3-6], concern about dorsiflexion malunion (which has been noted in association with as many as 28% of procedures performed with that technique[3,4,7,8]) has prompted the development of surgical alternatives. In an attempt to reliably control the sagittal position of the first metatarsal, an increasing number of surgeons have employed the proximal chevron and modified Ludloff osteotomies, both of which are performed through a medial approach as opposed to the dorsal approach used for the crescentic osteotomy[4,9,10].

In 1918, Ludloff[11] described an oblique osteotomy from the dorsal-proximal to the plantar-distal aspect of the first metatarsal, and the procedure was performed without internal

Disclosure: The authors did not receive any outside funding or grants in support of their research for or preparation of this work. Neither they nor a member of their immediate families received payments or other benefits or a commitment or agreement to provide such benefits from a commercial entity. No commercial entity paid or directed, or agreed to pay or direct, any benefits to any research fund, foundation, division, center, clinical practice, or other charitable or nonprofit organization with which the authors, or a member of their immediate families, are affiliated or associated.

fixation. Cisar et al.[12] reported on the performance of the technique with internal fixation in 1983. The procedure recently gained renewed attention when Myerson[13] and Saxena and McCammon[14] reported promising results when internal fixation was added. While maintaining the originally described orientation of the osteotomy, Myerson[13] modified the technique by inserting the proximal screw without fully tightening it before completing the osteotomy at the plantar cortex. In this manner, the surgeon retains control of the osteotomy throughout the procedure because the first intermetatarsal angle is corrected with rotation of the dorsal fragment around the partially secured proximal screw. The modified Ludloff osteotomy has been extensively investigated in biomechanical and mathematical studies[15-18]. The published short to intermediate-term results of the modified Ludloff osteotomy have suggested a favorable outcome in the hands of the inventor of its modifications[10]. We evaluated the intermediate-term results of the modified Ludloff osteotomy in a prospective study.

Materials and Methods

Between 1998 and 2000, 113 patients (125 feet) at two institutions underwent corrective surgery with use of the modified Ludloff osteotomy for the treatment of symptomatic hallux valgus. In four patients, the Ludloff osteotomy was performed as a revision procedure after the failure of a Keller-Brandes procedure. As part of the distal soft-tissue procedure, a lateral release was performed in all 125 feet. Nine patients (nine feet), including one of the four patients who had had a previous Keller-Brandes procedure, were lost to follow-up, and another patient died of a cause that was unrelated to the corrective bunion surgery. The other three patients who had had a previous Keller-Brandes procedure and one patient with general pain and a history of drug abuse were also excluded from the study. Thus, this prospectively followed cohort comprised ninety-nine patients (111 feet), including nine men and ninety women with an average age (and standard deviation) of 56 ± 13 years (range, twenty to seventy-eight years). Postoperatively, the patients were seen for weekly office visits for the first six weeks and were then evaluated again after a mean duration of follow-up of 34 ± 8 months (range, eighteen to fifty-six months). The surgical technique was standardized, and the operations were performed by a fellowship-trained foot and ankle surgeon (H.-J.T., M.E.E.), one at each institution. Follow-up evaluations were performed by an independent observer (F.G., S.B.A. Jr.), one at each institution.

The indication for the modified Ludloff osteotomy was a symptomatic hallux valgus deformity with a first intermetatarsal angle of ≥15°. The hallux valgus angle did not influence our decision-making. The contraindications to the procedure were the same as those for other proximal first metatarsal osteotomies, i.e., osteoarthritis of the first metatarsophalangeal joint and severe instability of the first tarsometatarsal joint (as determined on the basis of clinical evaluation and lateral radiographs demonstrating gapping of the first tarsometatarsal joint). All patients had had a failure of a trial of nonoperative management consisting of shoe-wear modification.

Operative Technique

The procedure typically is performed with use of peripheral nerve block with or without tourniquet control. A dorsal 3-cm longitudinal incision is made over the first web space. The lateral joint capsule and the metatarsosesamoid ligament are divided immediately superior to the lateral sesamoid. The transverse and oblique tendons of the adductor hallucis are released. The lateral capsule is fenestrated at the first metatarsophalangeal joint, and a varus stress is applied to the hallux to complete the lateral release. The transverse intermetatarsal ligament is not routinely divided.

A midaxial skin incision is made over the medial aspect of the first metatarsophalangeal joint, and an L-shaped medial capsulotomy is performed. Next, the metatarsal shaft is exposed with two Hohmann retractors. From the medial side, an oblique first metatarsal osteotomy is performed from the dorsal-proximal aspect of the first metatarsal (immediately distal to the first tarsometatarsal joint) to the plantar-distal aspect of the first metatarsal (immediately proximal to the sesamoid complex). The medial-to-lateral orientation of the saw blade limits the potential for dorsiflexion of the distal fragment, and, to further combat this risk, the osteotomy is routinely oriented 10° plantarward. Only the dorsal two-thirds of the osteotomy is initially performed (Fig. 1, *A*). A guide-wire for a 3.0-mm cannulated screw (Synthes, Paoli, Pennsylvania) is then inserted in the proximal aspect of the dorsal fragment, perpendicular to the osteotomy, and is overdrilled. The first 3.0-mm screw is then inserted into the drill-hole without full compression, and the osteotomy is then completed (Fig. 1, *B*). The plantar fragment is gently pulled medially with use of a towel clip, and the dorsal fragment is rotated laterally with gentle thumb pressure applied to the medial aspect of the first metatarsal head (Fig. 1, *C*). After the desired correction is confirmed fluoroscopically, the first screw is tightened to secure the osteotomy site. A second screw is then inserted from plantar to dorsal across the distal aspect of the osteotomy site (Fig. 1, *D*). With protection of the plantar soft tissues, the second screw must be directed as perpendicular to the first metatarsal as possible; if this second screw is placed obliquely with a lag technique, the correction of the first metatarsal angle may be lost. With correction of large intermetatarsal angles, some degree of oblique screw positioning is required to achieve adequate screw purchase. In these cases, we recommend that the osteotomy site be stabilized with a clamp when the second screw is tightened. Once appropriate correction has been achieved, the medial eminence of the first metatarsal head is excised in line with the metatarsal shaft. After skin closure, the foot is wrapped in a traditional, mildly compressive bunion dressing.

Aftercare

Postoperative weight-bearing and immobilization is standardized. Provided that satisfactory fixation of the osteotomy site is achieved intraoperatively, the patient is permitted to walk immediately in a postoperative shoe, bearing weight on the heel only. In the rare instance in which fixation is not optimal, we recommend the use of a short leg walking cast for

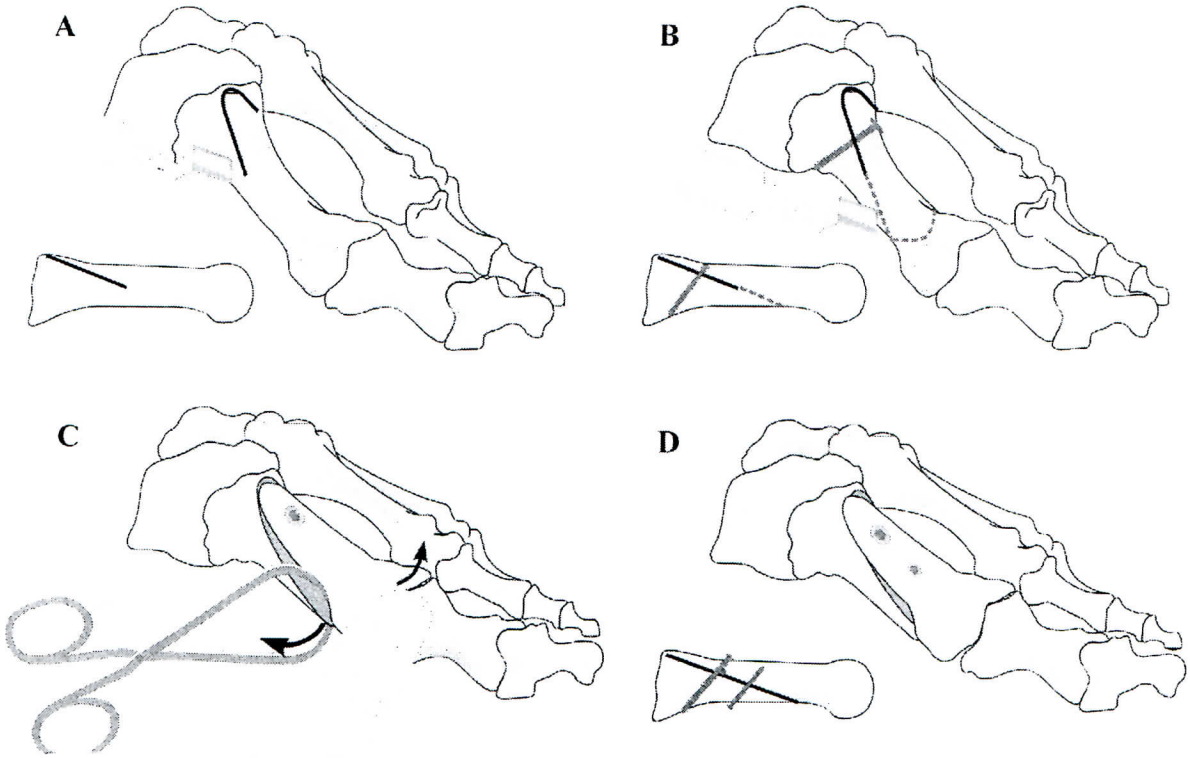

Fig. 1

Illustrations depicting the modified Ludloff osteotomy. *A:* Only the dorsal two-thirds of the osteotomy is initially performed. *B:* After the insertion of a 3.0-mm cannulated screw without full compression in the proximal aspect of the dorsal fragment, the osteotomy is completed. *C:* With use of a towel clip, the plantar fragment is gently pulled medially, and the dorsal fragment is rotated laterally with gentle thumb pressure applied to the medial aspect of the first metatarsal head. *D:* After the desired correction is confirmed fluoroscopically, the first screw is tightened to secure the osteotomy site and a second screw is then inserted from plantar to dorsal across the distal aspect of the osteotomy site. (Reproduced, with modification, from: Trnka H-J, Hofstätter S. The Ludloff osteotomy. Tech Foot Ankle Surg. 2005;4:263-8. Reprinted with permission.)

six weeks. Once there is radiographic evidence of healing at the osteotomy site, transfer of weight to the forefoot in a regular shoe is advanced, typically at six weeks. When osseous callus formation is noted at the osteotomy site on the six-week radiographs, we recommend delaying transfer of weight-bearing onto the forefoot to eight to ten weeks.

Evaluation

All patients underwent physical examination and assessment with use of the American Orthopaedic Foot and Ankle Society (AOFAS) forefoot-metatarsophalangeal-interphalangeal scale[19] preoperatively and at the time of the most recent follow-up by one observer at each institution who did not participate in the operative procedures (S.G.H., F.G., S.B.A. Jr.). The validated 100-point AOFAS scoring system combines subjective and objective data to evaluate the clinical parameters of pain (40 points), function (45 points), and alignment (15 points). With use of a goniometer, the range of motion of the hallux metatarsophalangeal joint was measured by passively positioning the joint in maximum flexion and maximum extension. Weight-bearing anteroposterior, oblique, and lateral radiographs of the foot were made preoperatively and at the time of follow-up. Simulated weight-bearing or non-weight-bearing radiographs of the foot were made in the immediate postoperative period. The hallux valgus and intermetatarsal angles were measured on dorsoplantar weight-bearing radiographs as described by Smith et al.[20], with the axis of the first metatarsal being defined as a line from the center of the head to the center of the base of the first metatarsal. The sesamoid position was evaluated by measuring the position of the medial sesamoid relative to the same bisecting line of the first metatarsal shaft and was classified as grade 0 to 3[20] (Fig. 2). Union was determined on the basis of the identification of bridging trabeculation at the osteotomy site in at least two of the three radiographic planes. Immediate postoperative radiographs also served to identify osseous callus at the osteotomy site, which was suggestive of less-than-optimal fixation and motion. To determine shortening of the first metatarsal following the modified Ludloff osteotomy, we used a method described by Mitchell et al.[21] and by one of us (H.-J.T.) and colleagues[22]. Measurements

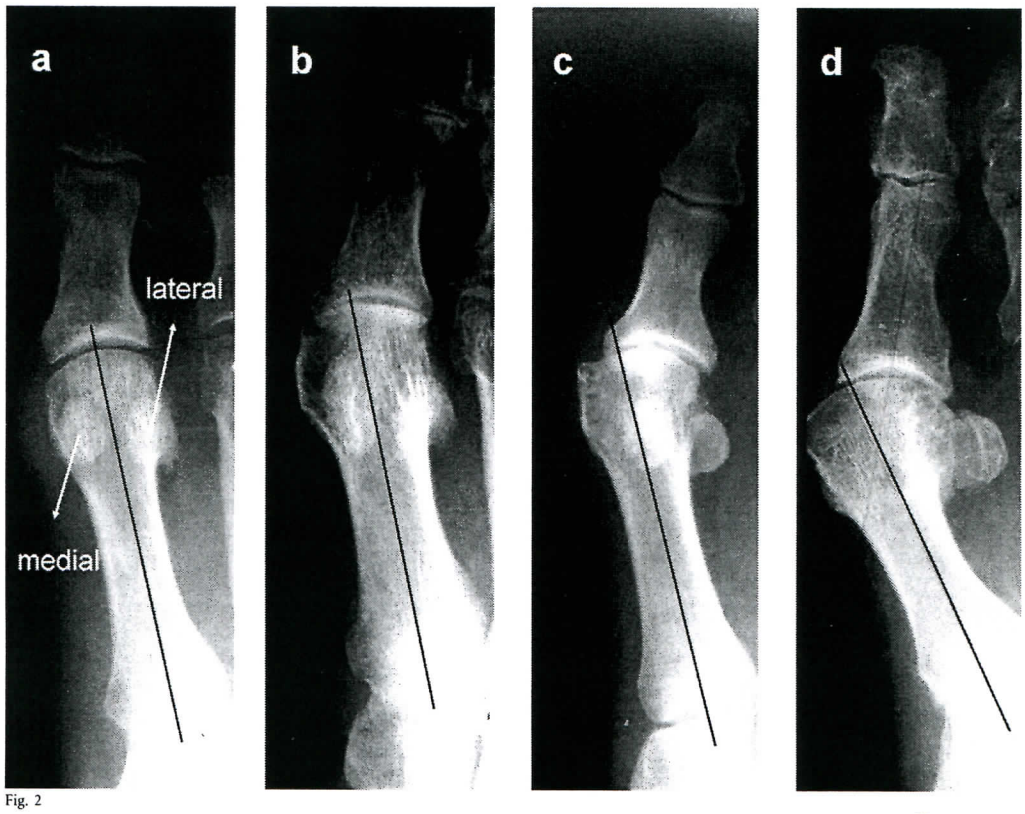

Fig. 2

Radiographs illustrating the classification of medial sesamoid displacement according to the method of Smith et al.[20]. *a:* Grade 0 is defined as no displacement of the sesamoid relative to the longitudinal axis of the first metatarsal. *b:* Grade 1 is defined as overlap of ≤50% of the sesamoid to the longitudinal axis of the first metatarsal. *c:* Grade 2 is defined as overlap of >50% of the sesamoid to the longitudinal axis of the first metatarsal. *d:* Grade 3 is defined as complete displacement of the sesamoid beyond the longitudinal axis of the first metatarsal.

were made by setting up a ratio between the lengths of the second metatarsal as shown on the preoperative and postoperative radiographs and the length of the first metatarsal as shown on the preoperative radiograph. Specifically, the amount of shortening was determined according to the formula $S = D - B \times (C/A)$, where S represents the amount of shortening, D represents the length of the first metatarsal as measured postoperatively, B represents the length of the first metatarsal as measured preoperatively, C represents the length of the second metatarsal as measured postoperatively, and A represents the length of the second metatarsal as measured preoperatively.

Statistical Methods

The Wilcoxon signed-rank test (two-tailed) was used to determine significant differences between the preoperative and follow-up AOFAS total scores and subscores for pain, function, and alignment. The same method was applied to compare range of motion of the metatarsophalangeal joint and all radiographic measurements (intermetatarsal angle, hallux valgus angle, and sesamoid position) preoperatively and at the time of follow-up. The Mann-Whitney U test was used to compare clinical outcomes and radiographic results between the sixty-three patients (seventy-two feet) who were sixty years of age or younger (range, twenty to sixty years) and the thirty-six patients (thirty-nine feet) who were more than sixty years of age (range, sixty-one to seventy-eight years). This separation at sixty years of age was chosen arbitrarily. Statistical analysis was performed by an independent statistician (J.G.H.) who was not directly involved in the clinical aspect of this investigation. The level of significance was set as $p < 0.05$.

Results

Clinical Outcome

After a mean duration of follow-up of thirty-four months, the patient-rated outcome was excellent for sixty-three feet (57%), good for twenty-six (23%), fair for seventeen (15%), and poor for five (5%).

The mean total AOFAS score improved significantly from 53 ± 11 points (range, 20 to 78 points) preoperatively to 88 ± 13 points (range, 44 to 100 points) at the time of follow-

TABLE I Clinical and Radiographic Data on the One Hundred and Eleven Feet

	Maximum Score *(points)*	Preoperative*	Follow-up*†	P Value‡
AOFAS score§ *(points)*				
All feet				
Overall	100	53 ± 11 (20 to 78)	88 ± 13 (44 to 100)	<0.0001
Pain	40	20 ± 9 (0 to 30)	37 ± 6 (20 to 40)	<0.0001
Function	45	32 ± 7 (10 to 45)	38 ± 6 (10 to 45)	<0.0001
Alignment	15	1.2 ± 2.8 (0 to 8)	13 ± 4 (0 to 15)	<0.0001
Feet with callus	100	41 ± 12 (20 to 62)	81 ± 16 (52 to 100)	0.0002
Feet without callus	100	47 ± 11 (24 to 78)	89 ± 13 (44 to 100)	<0.0001
Hallux valgus angle *(deg)*		35 ± 7 (16 to 66)	9 ± 9 (–14 to 32)	<0.0001
First intermetatarsal angle *(deg)*		17 ± 2 (15 to 24)	8 ± 3 (1 to 20)	<0.0001
Sesamoid displacement *(grade)*		2.7 ± 0.5 (0 to 3)	0.8 ± 0.7 (0 to 3)	<0.0001

*The values are given as the mean and the standard deviation, with the range in parentheses. †The mean duration of follow-up was thirty-four months. ‡Wilcoxon signed-rank two-tailed test. The p values pertain to the comparisons between the preoperative and follow-up examinations. The level of significance was set at $p < 0.05$. §AOFAS = American Orthopaedic Foot and Ankle Society.

up ($p < 0.0001$) (Table I). Comparisons of the mean preoperative and follow-up AOFAS subscores for pain, function, and alignment also revealed significant differences. The mean AOFAS pain subscore improved from 20 ± 9 points (range, 0 to 30 points) preoperatively to 37 ± 6 points (range, 20 to 40 points) at the time of follow-up ($p < 0.0001$). The mean AOFAS function subscore improved from 32 ± 7 points (range, 10 to 45 points) preoperatively to 38 ± 6 points (range, 10 to 45 points) at the time of follow-up ($p < 0.0001$). The mean AOFAS alignment subscore improved from 1.2 ± 2.8 points (range, 0 to 8 points) preoperatively to 13 ± 4 points (range, 0 to 15 points) at the time of follow-up ($p < 0.0001$). Preoperatively, all 111 feet had symptoms related to hallux valgus; the pain was described as mild in twenty-seven feet, moderate in seventy-three, and severe in eleven. At the time of final follow-up, twenty-four feet (22%) were symptomatic at the hallux or first ray; the pain was described as mild in sixteen and moderate in eight. No patient reported severe forefoot pain at the time of the most recent follow-up. With regard to the use of pain medication, forty-three patients (fifty-five feet; 50%) used nonsteroidal antirheumatic drugs for one week or less, and, by four weeks, eighty-eight patients (ninety-five feet; 86%) were not taking nonsteroidal antirheumatic drugs.

The mean range of motion of the hallux metatarsophalangeal joint decreased from 69° ± 19° (range, 10° to 110°) preoperatively to 59° ± 21° (range, 0° to 110°) at the time of the most recent follow-up ($p < 0.0001$). The mean dorsiflexion decreased from 53° ± 19° (range, 10° to 90°) preoperatively to 47° ± 18° (range, 0° to 110°) at the time of the most recent follow-up, and the mean plantar flexion decreased from 16° ± 11° (range, 0° to 45°) preoperatively to 12° ± 12° (range, 0° to 40°) at the time of the most recent follow-up.

Preoperatively, there was no significant difference between the mean total AOFAS score for patients who were sixty years of age or less and that for the patients who were more than sixty years of age (57 ± 11 compared with 52 ± 13 points; $p = 0.37$). At the time of follow-up, the mean total AOFAS score for the patients in the younger age-group was significantly higher than that for the patients in the older age-group (91 ± 12 points compared with 83 ± 17 points; $p = 0.0057$).

Radiographic Results

Significant differences were observed between the mean preoperative and follow-up measurements for the first intermetatarsal angle, the hallux valgus angle, and sesamoid positions. The mean intermetatarsal angle was 17° ± 2° (range, 15° to 24°) preoperatively and 8° ± 3° (range, 1° to 20°) at the time of the most recent follow-up ($p < 0.0001$). The mean hallux valgus angle was 35° ± 7° (range, 16° to 66°) preoperatively and 9° ± 9° (range, −14° to 32°) at the time of the most recent follow-up ($p < 0.0001$). The average correction was 9° ± 2° for the first intermetatarsal angle and 26° ± 8° for the hallux valgus angle. The mean sesamoid position was grade 2.7 ± 0.5 (range, 0 to 3) preoperatively and grade 0.8 ± 0.7 (range, 0 to 3) at the time of follow-up ($p < 0.0001$) (Figs. 3-A and 3-B).

For the group of patients who were more than sixty years of age, the mean hallux valgus angle was 33° ± 6° (range, 16° to 46°) preoperatively and 7° ± 6° (range, –10° to 25°) at the time of the most recent follow-up ($p < 0.0001$) and the mean intermetatarsal angle was 17° ± 2° (range, 15° to 23°) preoperatively and 7° ± 3° (range, 2° to 14°) at the time of the most recent follow-up ($p < 0.0001$). For the group of patients who were sixty years of age or less, the mean hallux valgus angle was 37° ± 9° (range, 20° to 66°) preoperatively and 11° ± 10° (range, –14° to 32°) at the time of the most recent follow-up ($p < 0.0001$) and the mean intermetatarsal angle was 17° ± 2° (range, 15° to 24°) preoperatively and 8° ± 4° (range, 1° to 20°) at the time of the most recent follow-up ($p < 0.0001$). Thus, both groups demonstrated significant improvement

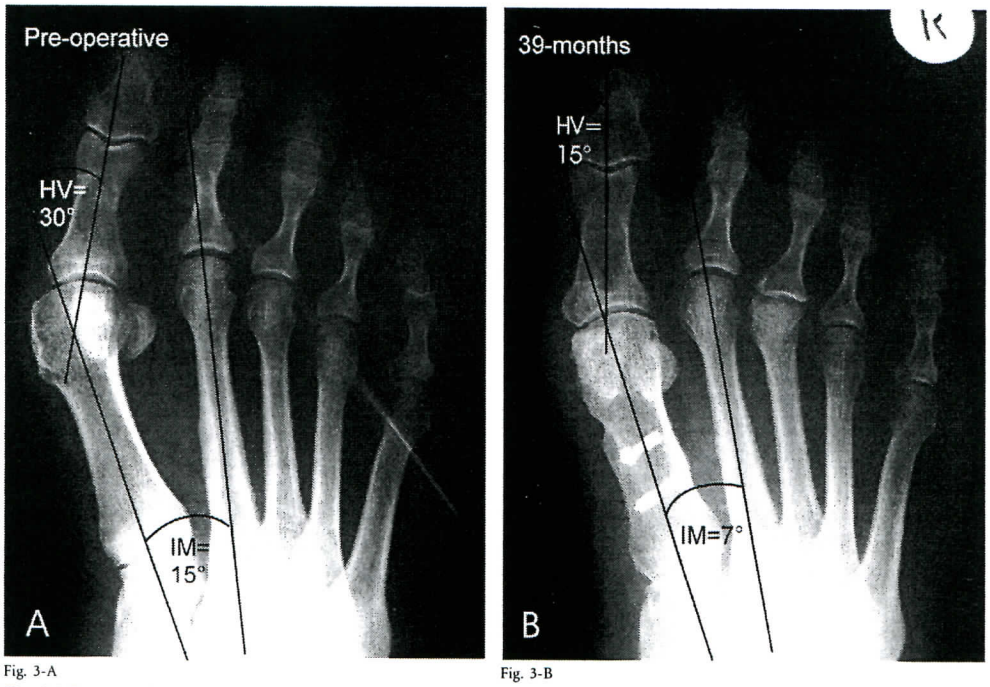

Fig. 3-A Fig. 3-B

Fig. 3-A Preoperative radiograph of the foot of a fifty-three-year-old woman with metatarsus primus varus and a severe hallux valgus deformity. At this time, the AOFAS score was 45 points. **Fig. 3-B** Radiograph made thirty-nine months after the patient underwent a Ludloff osteotomy. At this time, the AOFAS score was 95 points. The patient was very satisfied with the result, although the range of motion in the first metatarsophalangeal joint had decreased from 75° preoperatively to 50° at the time of follow-up. HV = hallux valgus. IM = intermetatarsal angle.

in terms of the hallux valgus and first intermetatarsal angle measurements.

At the time of the most recent follow-up, radiographs suggested that all osteotomy sites had united and no lateral weight-bearing radiograph demonstrated a dorsiflexion malunion. On the basis of the relative lengths of the first and second metatarsals, the first metatarsal shortened an average of 4% ± 2.9% (range, 1% to 11%). On the basis of the calculation suggested by one of us (H.-J.T.) and colleagues[22], the first metatarsal shortened an average of 2.2 ± 2.6 mm (range, 1 to 8 mm).

In eighteen feet (16%), an osseous callus formation was noted at the osteotomy site by six weeks. All eighteen feet had radiographic and clinical evidence of consolidation of the osteotomy site by ten weeks. The mean age was 63 ± 11 years (range, forty-two to seventy-eight years) for the patients with osseous callus formation, compared with 54 ± 12 years (range, twenty to seventy-eight years) for those without callus formation ($p = 0.006$). Comparison of the radiographic outcomes for osteotomy sites with and without osseous callus formation revealed a mean preoperative hallux valgus angle of 36° ± 12° (range, 16° to 66°) for the group with callus formation and of 35° ± 7° (range, 20° to 58°) for the group without callus formation ($p = 0.56$); at the time of follow-up, the hallux valgus angles were 12.2° ± 9° (range, −10° to 32°) and 9° ± 9° (range, −14° to 32°), respectively ($p = 0.1$). Preoperatively, the mean intermetatarsal angle was 18° ± 3° (range, 15° to 24°) for the group with callus formation and 18° ± 2° (range, 15° to 24°) for the group without osseous callus formation ($p = 0.4$); at the time of follow-up, the measurements were 9° ± 5° (range, 2° to 20°) and 7° ± 3° (range, 1° to 19°), respectively ($p = 0.05$).

Two patients had a delayed union, which was suggested by a persistent gap at the osteotomy site without osseous callus formation as seen on lateral radiographs made at six weeks. With postoperative cast immobilization and a protected weight-bearing status (for an additional two weeks in one patient and an additional four weeks in the other), successful union was observed in both patients without loss of correction.

Complications

One patient experienced displacement of the osteotomy site in the immediate postoperative period when she fell on the involved foot while not wearing a protective shoe. She underwent a reoperation and had a satisfactory outcome.

Recurrence

The average first intermetatarsal angle at the time of the most recent follow-up was 8° ± 3° (range, 1° to 20°). Recurrence of hallux valgus with an intermetatarsal angle of ≥15° occurred in

five feet (4.5%). Four of the feet with recurrence of deformity had clinical and radiographic evidence of first tarsometatarsal instability; two of these feet underwent revision surgery with a Lapidus procedure.

Hallux Varus

Hallux varus was noted in nine (8%) of the 111 feet. In this group, the hallux valgus angle averaged −8° ± 4° (range, −14° to −2°) and the intermetatarsal angle averaged 4° ± 3° (range, 2° to 8°). While hallux varus was noted radiographically, only two of these nine feet had symptoms at the first metatarsophalangeal joint or the medial aspect of the hallux. One of these two feet was treated with an extensor hallucis longus transfer, and the second was treated with a first metatarsophalangeal joint arthrodesis.

Transfer Metatarsalgia

Twenty-one patients (twenty-one feet) presented with a plantar keratosis underneath a lesser metatarsal head before surgery. At the time of the most recent follow-up, a plantar keratosis was still present in only six of these twenty-one feet. Four other feet had development of new transfer metatarsalgia with a plantar keratosis under the second metatarsophalangeal joint, and one foot had symptomatic callus formation under both the second and third metatarsal heads. In this group of feet with newly developed transfer metatarsalgia, the average first metatarsal shortening was 3% ± 1.2% (range, 1.8% to 4.1%), or 2.5 ± 1.2 mm (range, 1.6 to 4 mm). As was the case for all feet in the present study, none of the feet with transfer metatarsalgia had a dorsiflexed malunion of the first metatarsal.

First Metatarsophalangeal Joint Stiffness and Arthrosis

First metatarsophalangeal joint stiffness (with a range of motion of ≤30°) was observed in fourteen feet (13%). Only four of these feet had radiographic findings suggestive of arthrosis (joint-space narrowing), and, on review of the preoperative radiographs, two of these four feet had had mild arthritic changes prior to the corrective surgery. Of the ten feet without radiographic signs of arthrosis, only five were in patients who reported symptoms in the affected joint, despite the fact that all ten feet had a first metatarsophalangeal joint motion arc of ≤30° (average, 17° ± 8°; range, 5° to 30°). Two of the four feet with evidence of arthrosis on follow-up radiographs underwent revision surgery: one was treated with a first metatarsophalangeal joint arthrodesis, and the second was treated with a Keller resection arthroplasty.

Infection

Three patients (three feet; 2.7%) had a superficial wound infection; all were managed uneventfully with local wound care and oral antibiotics.

Prominent and/or Painful Hardware

Five patients (five feet; 4.5%) noticed prominent hardware on the dorsal aspect of the metatarsal, and three underwent hardware removal.

Discussion

This present study describes the results for a series of consecutive patients who were managed with a Ludloff osteotomy at two institutions by two experienced foot and ankle fellowship-trained surgeons. The fact that two institutions and two surgeons were included was both an advantage and a limitation of the study. It was an advantage in that it allowed us to present our early experience with the complications associated with the technique in order to help others to avoid them. It was a limitation in that it was not possible to have one single independent investigator perform the follow-up, but at least the surgeons were not involved in the follow-up.

Numerous proximal first metatarsal osteotomies have been described for the treatment of moderate to severe symptomatic hallux valgus, and most, when combined with a distal soft-tissue procedure, are effective for the correction of hallux valgus deformity associated with metatarsus primus varus. Arguably, the proximal crescentic osteotomy[3,6,23] represents the criterion standard against which all other proximal osteotomies are measured. There is little doubt that excellent results can be achieved with the proximal crescentic osteotomy, particularly given the comprehensive teaching of this technique by the orthopaedists who popularized the procedure[3,6,23,24]. However, there is a risk of dorsiflexion occurring at the osteotomy site[4,8,25], even in the hands of surgeons who are familiar with the technique[3,25]. Despite recent descriptions of how this tendency for dorsiflexion can be avoided[25], the risk of dorsiflexion malunion has prompted some surgeons to seek alternative approaches[4,9,10,12,14].

The Ludloff osteotomy (without fixation) was first described almost a century ago[11]. Recent modifications to the original technique, including the use of internal fixation, quite reliably eliminate the risk of creating a dorsiflexion malunion of the first metatarsal[10,12-14]. Moreover, these modifications allow the surgeon to maintain optimal control of the osteotomy throughout the procedure. Specifically, this is accomplished with temporary fixation between the two first metatarsal fragments, which is established prior to completion of the osteotomy[10,13,15,26]. The favorable results reported in association with this method prompted us to independently determine if the results can be reproduced.

Our findings suggest that the intermediate-term outcomes of the modified Ludloff osteotomy combined with a distal soft-tissue procedure are comparable with those reported for the proximal crescentic osteotomy[6,23], for the proximal chevron osteotomy[4,9], and by other investigators who have used the modified Ludloff osteotomy[10,13]. In the present study of 111 osteotomies, the AOFAS score improved significantly from 53 points preoperatively to 88 points at a mean of thirty-four months, and the average intermetatarsal angle decreased from 17° to 8°. Chiodo et al.[10] presented the results of seventy modified Ludloff osteotomies after a mean duration of follow-up of thirty months. The mean AOFAS forefoot score improved from 54 to 91 points, and the mean first intermetatarsal angle decreased from 16° to 7°.

Markbreiter and Thompson[5] presented the results of twenty-five proximal crescentic osteotomies after a mean du-

ration of follow-up of five years. The mean AOFAS score improved from 47 points to 93 points, and the intermetatarsal angle decreased from 16° to 6°. In a prospective, randomized study, one of us (M.E.E.) and colleagues[4] assessed the results of forty-one proximal crescentic osteotomies at an average of twenty-four months postoperatively. The mean intermetatarsal angle decreased from 16° to 7°, and the mean AOFAS score improved from 51 to 92 points.

Published studies of the proximal chevron osteotomy have demonstrated similar results. One of us and colleagues[4] also assessed forty-three proximal chevron osteotomies at an average of twenty months after surgery and documented an average decrease of the intermetatarsal angle from 16° to 7° and an average improvement in the AOFAS score from 50 to 90 points. Sammarco et al.[9], in a prospective evaluation of fifty-one proximal chevron osteotomies, reported that the average intermetatarsal angle was corrected from 14° preoperatively to 6° after a mean duration of follow-up of eighteen months. Markbreiter and Thompson[5], in a retrospective study of twenty-five proximal chevron osteotomies, reported that the average AOFAS score increased from 53 to 93 points and that the average intermetatarsal angle decreased from 15° to 5°.

Similar to other first metatarsal surgical procedures designed to correct hallux valgus, the modified Ludloff osteotomy carries a risk of recurrence, hallux varus, shortening, dorsiflexion malunion, transfer metatarsalgia, delayed union, infection, and prominent or painful hardware.

The recurrence rate in our series of 111 Ludloff osteotomies was 4.5%, which is higher than the 1.4% rate reported by Chiodo et al. for the same procedure[10] but is within the range reported for the proximal crescentic osteotomy (3.7% to 4.8%)[4,6] and is similar to the rate reported for the proximal chevron osteotomy (4.6%)[4]. The 8% prevalence of hallux varus in the present investigation is comparable with the rates in other studies of proximal first metatarsal osteotomies (range, 6% to 16%)[4,8,10,27].

First metatarsal shortening and dorsiflexion malunion may lead to transfer metatarsalgia (overload of the lesser metatarsal heads). The average first metatarsal shortening in the present series was 2.2 mm, which was comparable with the values of 2.3 mm as reported by Chiodo et al.[10] and of 1.4 mm as reported by Saxena and McCammon[14]. In follow-up studies of the proximal crescentic osteotomy, dorsiflexion malalignment has ranged from 9% to 28%[3,4,7,8]. The rate of postoperative dorsiflexion following proximal chevron osteotomy has ranged from 0% to 3% in the literature[4,5,9]. In the present series, there was no case of dorsiflexion malunion of the first metatarsal, which was consistent with the findings reported by both Chiodo et al.[10] and Saxena and McCammon[14]. As mentioned above, a dorsiflexed first metatarsal may lead to transfer metatarsalgia. Markbreiter and Thompson[5], in their retrospective comparison of proximal chevron and crescentic osteotomies, failed to show a correlation between first metatarsal dorsiflexion malunion and transfer metatarsalgia. One of us (M.E.E.) and colleagues[4] stated that the prevalence of transfer metatarsalgia may be higher in first metatarsals shortened and malunited in dorsiflexion, but that study lacked the statistical power to prove that point. In the present series of modified Ludloff osteotomies, transfer metatarsalgia developed in 4% of the feet, similar to the rates of 0% to 3% reported for proximal chevron osteotomy[4,5,9] and less than the rates of 5% to 21% reported for proximal crescentic osteotomy[4,27].

As with many orthopaedic procedures, osteopenia may compromise the quality of fixation of a proximal first metatarsal osteotomy; this was our experience with the modified Ludloff osteotomy. During the immediate postoperative follow-up period, we observed a 16% rate of osseous callus formation at the osteotomy site, a finding suggestive of motion between the two first metatarsal fragments despite fixation with two screws in all patients. As the average age was fifty-four years for the patients without osseous callus at the osteotomy site as compared with sixty-three years for those with osseous callus, and as older patients are more likely to have osteopenia, we surmised that osteopenia may be responsible for less rigid fixation of the osteotomy site. Anecdotally, we also noted that poor orientation of the screws or a short osteotomy that fails to optimize the surface area for healing also may contribute to motion at the osteotomy site and osseous callus formation. Patients who had development of a callus at the osteotomy site had healing with additional immobilization and protected weight-bearing, and we recommend this approach for such patients.

With regard to delayed union, we observed a delay in healing in 2% of our patients, compared with 4% of those reported by Chiodo et al.[10]. In our opinion, delayed union is distinct from callus formation at the osteotomy site suggestive of motion at the osteotomy site. A persistent gap at the osteotomy site, visible only on the lateral radiograph six weeks after the osteotomy, defines a delayed union. In our opinion, delayed union is associated with satisfactory fixation but with an incongruent osteotomy, or perhaps it is a sequela of heat necrosis from the oscillating saw blade. Empirically, we treat a delayed union with extended immobilization and protected weight-bearing until bridging trabeculation over the majority of the osteotomy site is seen radiographically. In both cases of delayed union in the present series, this approach was successful.

The wound infection rate in the present study was 2.7%. All infections cleared uneventfully with local wound care and oral antibiotics. This rate is consistent with those reported in the literature for proximal crescentic osteotomy (2.4% to 6.4%)[3,4] and proximal chevron osteotomy (0% to 4.6%)[4,5]. Chiodo et al.[10] reported a 7% rate of prominent hardware requiring removal. In the present study, hardware removal was necessary in 3% of the 111 feet. This rate is much lower than the rates for crescentic osteotomy, which have been reported to be as high as 52%[4,5,10,27].

While the clinical outcome for patients who were sixty years of age or younger was significantly better than that for patients who were more than sixty years of age, the radiographic results at the time of follow-up were comparable for these arbitrarily assigned groups. The present study does not offer an explanation for this difference, and we simply report this observation.

We conclude that the modified Ludloff osteotomy combined with a distal soft-tissue procedure yields satisfactory outcomes and low complication rates that are comparable with those associated with other methods employing a proximal metatarsal osteotomy for the correction of moderate to severe hallux valgus. Like other proximal metatarsal osteotomies that are performed from the medial aspect of the metatarsal, the modified Ludloff osteotomy has a low risk for dorsiflexion malunion. The technique affords the surgeon control of the osteotomy throughout the procedure as initial fixation between the two fragments is established before completion of the osteotomy. We recommend careful radiographic evaluation in the immediate postoperative period, particularly for patients over the age of sixty years and those with suspected osteopenia. Such patients should be restricted from bearing weight on the forefoot for a longer period of time in comparison with younger patients who have satisfactory fixation of the osteotomy site. Furthermore, if osseous callus at the osteotomy site is noted postoperatively, temporary immobilization in a weight-bearing cast should be considered. ■

H.-J. Trnka, MD
S.G. Hofstaetter, MD
Foot and Ankle Center Vienna/Fusszentrum Wien, Alserstraße 43/8d, 1080 Vienna, Austria. E-mail address for H.-J. Trnka: trnka@fusszentrum.at. E-mail address for S.G. Hofstaetter: stefanhofstaetter@gmx.at

J.G. Hofstaetter, MD
Department of Orthopaedics, Vienna General Hospital, Medical University of Vienna, Waehringer Guertel 18-20, A-1090-Vienna, Austria. E-mail address: jochen.hofstaetter@meduniwien.ac.at

F. Gruber, MD
Orthopaedic Hospital Gersthof, Wielemansgasse 28, 1180 Vienna, Austria. E-mail address: florian.gruber@wienkav.at

S.B. Adams Jr., MD
M.E. Easley, MD
Division of Orthopaedic Surgery, Box 3000 (S.B.A. Jr.) and Box 2950 (M.E.E.), Duke University Medical Center, Durham, NC 27710. E-mail address for S.B. Adams Jr: adams121@mc.duke.edu. E-mail address for M.E. Easley: easle004@mc.duke.edu

References

1. Jahss MH, Troy AI, Kummer F. Roentgenographic and mathematical analysis of first metatarsal osteotomies for metatarsus primus varus: a comparative study. Foot Ankle. 1985;5:280-321.

2. Kummer FJ. Mathematical analysis of first metatarsal osteotomies. Foot Ankle. 1989;9:281-9.

3. Mann RA. Distal soft tissue procedure and proximal metatarsal osteotomy for correction of hallux valgus deformity. Orthopedics. 1990;13:1013-8.

4. Easley ME, Kiebzak GM, Davis WH, Anderson RB. Prospective, randomized comparison of proximal crescentic and proximal chevron osteotomies for correction of hallux valgus deformity. Foot Ankle Int. 1996;17:307-16.

5. Markbreiter LA, Thompson FM. Proximal metatarsal osteotomy in hallux valgus correction: a comparison of crescentic and chevron procedures. Foot Ankle Int. 1997;18:71-6.

6. Mann RA, Rudicel S, Graves SC. Repair of hallux valgus with a distal soft-tissue procedure and proximal metatarsal osteotomy. A long-term follow-up. J Bone Joint Surg Am. 1992;74:124-9.

7. Brodsky JW, Beischer AD, Robinson AH, Westra S, Negrine JP, Shabat S. Surgery for hallux valgus with proximal crescentic osteotomy causes variable postoperative pressure patterns. Clin Orthop Relat Res. 2006;443:280-6.

8. Zettl R, Trnka HJ, Easley M, Salzer M, Ritschl P. Moderate to severe hallux valgus deformity: correction with proximal crescentic osteotomy and distal soft-tissue release. Arch Orthop Trauma Surg. 2000;120:397-402.

9. Sammarco GJ, Brainard BJ, Sammarco VJ. Bunion correction using proximal Chevron osteotomy. Foot Ankle. 1993;14:8-14.

10. Chiodo CP, Schon LC, Myerson MS. Clinical results with the Ludloff osteotomy for correction of adult hallux valgus. Foot Ankle Int. 2004;25:532-6.

11. Ludloff K. Die Beseitigung des Hallux valgus durch die schräge planta-dorsale Osteotomie des Metatarsus I. Arch Klin Chir. 1918;110:364-87.

12. Cisar J, Holz U, Jenninger W, Uhlig C. Die Osteotomie nach Ludloff bei der Hallux-valgus-Operation. [Ludloff's osteotomy in hallux valgus surgery]. Aktuelle Traumatol. 1983;13:247-9. German.

13. Myerson MS. The Ludloff osteotomy. Joint meeting of the American Orthopaedic Foot & Ankle Society and the Japanese Society for Surgery of the Foot. 1997 Nov 13-15; Waikoloa, HI.

14. Saxena A, McCammon D. The Ludloff osteotomy: a critical analysis. J Foot Ankle Surg. 1997;36:100-5;159-60.

15. Nyska M, Trnka HJ, Parks BG, Myerson MS. Proximal metatarsal osteotomies: a comparative geometric analysis conducted on sawbone models. Foot Ankle Int. 2002;23:938-45.

16. Nyska M. Principles of first metatarsal osteotomies. Foot Ankle Clin. 2001;6:399-408.

17. Lian GJ, Markolf K, Cracchiolo A 3rd. Strength of fixation constructs for basilar osteotomies of the first metatarsal. Foot Ankle. 1992;13:509-14.

18. Trnka HJ, Parks BG, Ivanic G, Chu IT, Easley ME, Schon LC, Myerson MS. Six first metatarsal shaft osteotomies: mechanical and immobilization comparisons. Clin Orthop Relat Res. 2000;381:256-65.

19. Kitaoka HB, Alexander IJ, Adelaar RS, Nunley JA, Myerson MS, Sanders M. Clinical rating systems for the ankle-hindfoot, midfoot, hallux, and lesser toes. Foot Ankle Int. 1994;15:349-53.

20. Smith RW, Reynolds JC, Stewart MJ. Hallux valgus assessment: report of research committee of American Orthopaedic Foot and Ankle Society. Foot Ankle. 1984;5:92-103.

21. Mitchell CL, Fleming JL, Allen R, Glenney C, Sanford GA. Osteotomy-bunionectomy for hallux valgus. J Bone Joint Surg Am. 1958;40:41-60.

22. Trnka HJ, Mühlbauer M, Zembsch A, Hungerford M, Ritschl P, Salzer M. Basal closing wedge osteotomy for correction of hallux valgus and metatarsus primus varus: 10- to 22-year follow-up. Foot Ankle Int. 1999;20:171-7.

23. Dreeben S, Mann RA. Advanced hallux valgus deformity: long-term results utilizing the distal soft tissue procedure and proximal metatarsal osteotomy. Foot Ankle Int. 1996;17:142-4.

24. Mann RA. [Treatment of hallux valgus. Distal soft-tissue procedures and proximal metatarsal osteotomy]. Orthopade. 1996;25:302-7. German.

25. Jones C, Coughlin M, Villadot R, Golanó P. Proximal crescentic metatarsal osteotomy: the effect of saw blade orientation on first ray elevation. Foot Ankle Int. 2005;26:152-7.

26. Nyska M, Trnka HJ, Parks BG, Myerson MS. The Ludloff metatarsal osteotomy: guidelines for optimal correction based on a geometric analysis conducted on a sawbone model. Foot Ankle Int. 2003;24:34-9.

27. Thordarson DB, Leventen EO. Hallux valgus correction with proximal metatarsal osteotomy: two-year follow-up. Foot Ankle. 1992;13:321-6.