

## Dorsiflexion Contracture After the Weil Osteotomy: Results of Cadaver Study and Three-Dimensional Analysis

Hans-Jörg Trnka, MD\*†; Meir Nyska, MD\*§; Brent G. Parks, MSc\*; and Mark S. Myerson, MD\*  
Baltimore, MD; Vienna, Austria; and Jerusalem, Israel

### ABSTRACT

For metatarsalgia caused by a dislocated lesser metatarsophalangeal (MTP) joint and isolated over-long lesser metatarsals, surgical treatment options without sacrificing the joint are limited. Recently, the Weil osteotomy has been advocated for the treatment of this deformity. In our experience, preliminary results with this technique have revealed a high rate of dorsiflexion contracture of the MTP joints at follow-up. We performed a cadaver study and a three-dimensional analysis on sawbones to investigate this phenomenon.

In the cadaveric portion of this study, the second MTP joints of two fresh-frozen cadavers were dissected; the entire ray, with the metatarsal shaft, MTP joint, toe, and plantar fascia, was removed en bloc. After gross anatomic structures were photographed, a Weil osteotomy was performed at 25° relative to the long axis of the metatarsal shaft. The positions of muscles, ligaments, and tendons were noted and photographed before and after the osteotomy.

In the sawbones portion of this study, a Weil osteotomy was performed at four different angles (25°, 30°, 35°, and 40°) relative to the long axis of the metatarsal. To ensure reproducibility, the sawbone models were fixed proximally to a vertical milling machine with the second metatarsals inclined 15° to simulate the anatomic position. After making the cut, the plantar fragment was translated along the dorsal fragment proximally for a distance of 5 mm. Before and after the osteotomy, selected x, y, and z coordinates were obtained using a Microscribe 3D digitizer. Data analysis was performed with Microsoft Excel, and ANOVA was used to determine significant differences ( $p < 0.05$ ) between the various osteotomies.

Analysis of the cadaver dissection revealed that after the Weil osteotomy, the tendons of the interosseous muscles move dorsally with respect to the axis of the MTP joint

due to the depression of the plantar fragment of the metatarsal. The loss of their flexion effect on the joint permits the pull of the extensor to dorsiflex the toe. The size of the depression for the various osteotomies averaged: 25° osteotomy, 3.03 mm (range, 1.8 to 3.8 mm); 30° osteotomy, 3.2 mm (range, 1.9 to 4.0 mm); 35° osteotomy, 3.5 mm (range, 1.7 to 5.7 mm); and 40° osteotomy, 4.2 mm (range, 2.8 to 6.4 mm). Amounts of shortening relative to the long axis of the metatarsal for the various osteotomies averaged: 25° osteotomy, 5.03 mm (range, 4.77 to 5.30 mm); 30° osteotomy, 4.59 mm (range, 3.47 to 5.19 mm); 35° osteotomy, 4.27 mm (range, 2.87 to 5.00 mm); and 40° osteotomy, 3.65 mm (range, 3.20 to 4.31 mm).

According to our analysis, depression of the plantar fragment always occurs after a Weil osteotomy. This depression changes the center of rotation of the MTP joint, and the interosseous muscles then act more as dorsiflexors than as plantarflexors.

### INTRODUCTION

For metatarsalgia caused by a dislocated lesser metatarsophalangeal joint (MTP) and isolated over-long lesser metatarsals, surgical treatment options without sacrificing the joint are limited.<sup>3-5,7,10</sup> Recently, the Weil osteotomy<sup>1,11</sup> has been advocated for the treatment of this pathology. The theory of this procedure is that this oblique osteotomy of the metatarsal neck and shaft parallels the ground surface, providing controlled shortening of the metatarsal without additional depression. This procedure should allow reduction of the dislocated MTP joint without increasing plantar pressure.

Preliminary results with the Weil osteotomy have shown a high rate of reduction of dislocated MTP-joints, but subsequent dorsiflexion contracture was often seen and restricted plantarflexion was noted in 14 of 30 patients.<sup>8,11</sup> The objective of the current study was to investigate the changes in action forces after the Weil osteotomy, to determine if the hypothesis of shortening without depression with this oblique osteotomy is valid, and to explain the phenomenon of postoperative dorsiflexion contracture.

\*From the \*Department of Orthopaedic Surgery, The Union Memorial Hospital, Baltimore, Maryland; the †Department Orthopedic, Hospital Gersthof, Vienna, Austria; and the §Department of Orthopaedic Surgery, Hadassah-Hebrew University Medical Centers, Mount Scopus, Jerusalem, Israel

Address all correspondence and reprint requests to: Hans-Jörg Trnka, MD c/o Lynn Camire, Editor, Union Memorial Orthopedics, The Johnston Professional Building, #400, 3333 North Calvert St., Baltimore, MD 21218 (410-554-6668, fax: 410-554-2832; e-mail: lync@helix.org).

**MATERIALS AND METHODS**

**Anatomy**

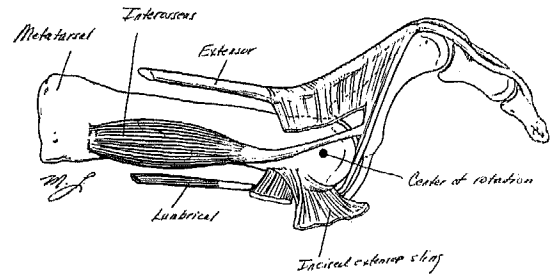
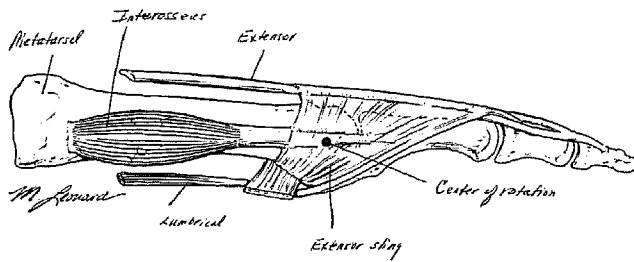
An appreciation of the anatomy of the lesser MTP joints is crucial to understanding the pathology and the potential changes after the Weil osteotomy around the MTP joint.

The central dorsal structure of the MTP joint is the extensor digitorum longus tendon. This muscle inserts with two lateral slips into the distal phalanx and with a middle bridle into the base of the middle phalanx of the toe. The extensor mechanism stabilizes this tendon at its dorsal position on the toe and connects the tendon sheath to the proximal phalanx of the toe. The function of the extensor digitorum longus tendon is to extend the proximal phalanx and the proximal interphalangeal joint if the proximal phalanx is in a flexed or neutral position. The extensor digitorum brevis tendon inserts into the base of the middle phalanx and extends the proximal interphalangeal joint. The extensor hood extends from the deep surface of the extensor longus tendon to the dorsal capsule of the MTP joint and the base of the

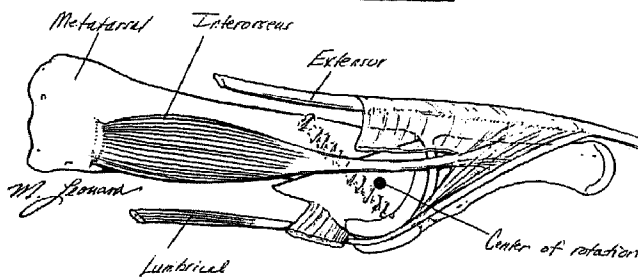
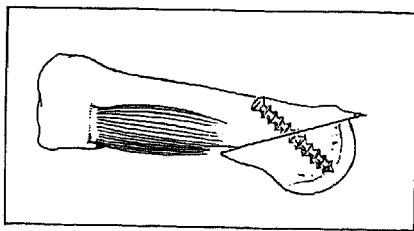
proximal phalanx. This structure and a fibroaponeurotic structure that extends from the MTP joint to the proximal interphalangeal joint hold the tendon in a central position.

The plantar plate has a substantial attachment to the proximal phalanx and the plantar fascia but, except for the collateral ligaments, it is without substantial fibrous attachment to the metatarsal head.<sup>6</sup> Antagonizers of the extensor mechanism are the flexor tendons, the plantar plate, and, to a certain extent, the intrinsic muscles. The intrinsic muscles of the lesser MTP joints are the plantar and dorsal interossei and the lumbricalis muscles. The dorsal interossei originate from the lateral surface of the metatarsals whereas the plantar interossei originate from the plantar medial surface of the metatarsal. The lumbricalis muscles arise from the intertendinous angle of the flexor digitorum tendon. Both interossei and the lumbricals insert on the base of the proximal phalanx. Their tendons pass plantar to the axis of their MTP joint. Their function is to hold the proximal phalanx in its neutral position.

The flexor digitorum longus tendon inserts into the



**Fig. 1.** Anatomic positions. (a, above): The center of the metatarsal head corresponds to the axis of the interosseus tendon in the normal toe. (b, above right): with dorsal subluxation or contracture of the second toe's MTP joint, the interosseus tendon is dorsal to the central axis of the metatarsal head. (c, below): after a Weil osteotomy, the MTP joint alignment improves, although the interosseus tendon remains dorsal to the central axis of the metatarsal.



distal phalanx of the toe and flexes the distal interphalangeal joint, whereas the flexor digitorum brevis inserts into the middle phalanx and flexes the proximal interphalangeal joint. Neither flexor tendon has an insertion into the proximal phalanx of the toe.<sup>2,9</sup>

Other stabilizing factors of the toes are interossei and the lumbricals. The second toe, the most frequent site of dorsal dislocation, has two dorsal interossei, but no plantar interossei. The lumbricals arise from the long flexor tendons and insert into the medial extensor mechanism. The tendons of the intrinsic muscles pass volar to the axis of motion at the MTP joint.<sup>9</sup> These relationships explain the action of these structures as flexors of the MTP joint. The major factor in dorsoplantar stability of the MTP joint is the plantar plate, formed from the plantar aponeurosis and the plantar joint capsule.

**Cadaver Study**

We thawed two fresh-frozen lower leg cadaver speci-

mens and immediately dissected the second MTP joints. Dissection was carried out by removing en bloc the entire ray, with the metatarsal shaft, MTP joint, toe, and plantar fascia. The positions of gross anatomic structures (e.g., muscles, ligaments, and tendons) were photographed and sketched. Then a Weil osteotomy was performed at 25° relative to the long axis of the metatarsal shaft, with the entry point positioned at the dorsal edge of the cartilage of the metatarsal head, i.e., at the junction between the cartilage and neck area. Then the anatomic positions were again noted and photographed (Fig. 1).

### Three-Dimensional (3D) Sawbone Analysis

Using sawbone models of the second metatarsal bone (Pacific Research Laboratories, Vashon, WA), we performed Weil osteotomies at four different angles (25°, 30°, 35°, and 40°) relative to the long axis of the metatarsal. For each angle, we shifted the distal segment of the metatarsal proximally (to equate with metatarsal shortening) 5 mm. To ensure reproducibility, the sawbone models were tightly fixed proximally in a vise to a vertical milling machine as test frame with the second metatarsals inclined 15° to simulate the anatomic position. A Microscribe 3D digitizer (Immersion Corp., San Jose, CA) was used to obtain the x, y, and z coordinates of selected points on the model. Three points (two over the dorsum and one at the most distal and plantar aspect of the metatarsal head) were used to establish a reference frame on the proximal end of each sample.

After securing the model in the vise, the digitizer was used to establish the reference frame at the proximal end of the second metatarsal and to obtain preoperative data. The osteotomy was then performed using a standard saw blade (Hall Zimmer 5023-138 blade, 0.4 mm thick, and 10 mm wide) mounted on standard mini Hall sagittal saw. The plane of the osteotomy was parallel to the ground surface, from the dorsal portion of the metatarsal head aiming proximally. The plantar fragment was shifted 5 mm proximally, as measured along the plane of the osteotomy. After the osteotomy was secured with a Kirschner wire, a second set of data points was obtained. Five sawbones were used for each different angle.

The following parameters were calculated for each sample: change in depression of the metatarsal head with respect to the long axis of the metatarsal, actual depression in millimeters with respect to the ground, measured shortening of the long axis of the metatarsal, and actual shortening along the horizontal plane (parallel to the ground).

Data analysis was performed with Microsoft Excel and analysis of variance was used to determine signifi-

cant differences between the various osteotomies ( $p < 0.05$ ).

## RESULTS

### Anatomic Dissection

The current cadaver dissection confirmed the gross anatomy findings of Sarrafian and Topouzian.<sup>9</sup> The dissection after the Weil osteotomy revealed that, due to the depression of the metatarsal head, the tendons of the intrinsic muscles passed dorsal to the axis of rotation of the MTP joint and the plantar plate loosened.

### 3D Sawbone Analysis

The results are presented graphically in Fig. 2. After 5 mm of displacement (shortening), the metatarsal head depressions (relative to the ground surface) for the Weil osteotomies were as follows (average  $\pm$  SD): 25°, 3.03  $\pm$  0.94 mm (range, 1.8 to 3.8 mm); 30°, 3.2  $\pm$  0.8 mm (range, 1.9 to 4.0 mm); 35°, 3.5  $\pm$  1.6 mm (range, 1.7 to 5.7 mm); and 40°, 4.2  $\pm$  1.4 mm (range, 2.8 to 6.4 mm). These values were not significantly different.

Actual shortening of the metatarsal along the horizontal plane after the Weil osteotomies were as follows (average  $\pm$  SD): 25°, 4.8  $\pm$  0.2 mm (range, 4.6 to 5.1 mm); 30°, 4.4  $\pm$  0.7 mm (range, 3.4 to 5.0 mm); 35°, 4.1  $\pm$  0.8 mm (range, 2.8 to 4.8 mm); and 40°, 3.5  $\pm$  0.5 mm (range, 3.1 to 4.2 mm). The difference in shortening between the 25° and 40° angulation was statistically significant ( $p = 0.02$ ).

## DISCUSSION

The indications for a Weil osteotomy are atraumatic dorsal dislocation of the lesser MTP joint, cross-over deformity, and isolated over-long lesser metatarsals (in selected cases). The generally recognized etiology of

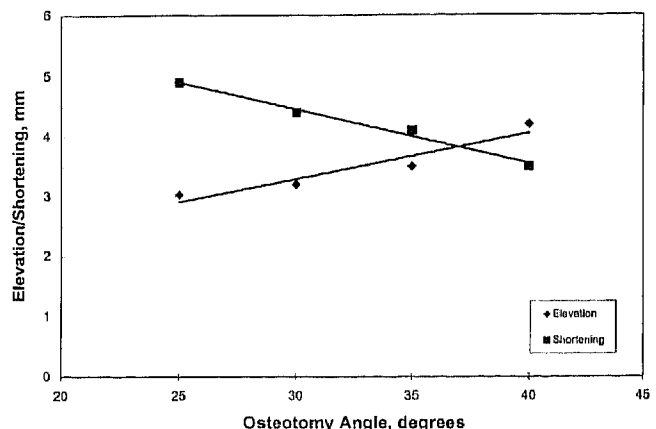


Fig. 2. Change in depression and shortening as a function of osteotomy angle.

the first condition is a muscular imbalance between the extensors (which insert into the proximal phalanx) and the flexors (which do not) around the MTP joint. This imbalance is a result of 1) the stretching or rupture of the plantar plate (due to overlength of the lesser metatarsals relative to the first metatarsal) or 2) pressure caused by concurrent hallux valgus or hammertoe deformity.

Preliminary results of the Weil procedure for dislocated lesser MTP joints<sup>11</sup> were promising, but the current authors and other clinicians have noted subsequent dorsiflexion contracture of the MTP joint. Although such contracture was not clinically significant and there were no patient complaints, the future consequences of this condition are unknown. To understand the cause of this condition and to propose a solution was the objective of the current investigation.

Clinically, it is assumed that the second metatarsal is at a 15° inclination relative to the ground. The hypothesis is that the Weil osteotomy is parallel with the ground surface and provides shortening, but no change in depression/elevation relative to the ground. In the saw-bone model, we were unable to achieve an osteotomy angle less than 25° relative to the long axis of the bone, with the result that the saw blade was deflected by the second cortex of the metatarsal. This was similar to intraoperative observations. As a result of not achieving less than a 25° angle of osteotomy, the plane of the cut was 10° relative to the ground surface. The relative inclination of the osteotomy leads to depression when the distal segment of the metatarsal is shifted. This was confirmed by our 3D analysis. The average depression, using a 25° osteotomy, was 3.03 mm; this value increased to 4.2 mm when using a 40° osteotomy.

The hypothesis of an osteotomy parallel to the ground surface was disproved. Importantly, depression of the metatarsal head changes the level of the axis of the MTP joint. The intrinsic muscles, acting as plantarflexors due to the fact that they pass plantar to the axis of the MTP joint, now become located through or dorsal to the axis and lose their flexion effect.

The plantar plate, already ruptured in cases of dislocated MTP joints, becomes looser after the shortening effect of the osteotomy because it has no direct insertion into the metatarsal head.

It is our opinion that the Weil osteotomy is the best treatment for dislocated MTP joints, but the results of the current study indicate that the Weil osteotomy is always associated with a subsequent depression of the metatarsal head. As a result of the change in the center

of motion of the metatarsal head, a dorsiflexion contracture may occur. The following interventions may prevent postoperative dorsiflexion contracture: 1) lengthening the extensor tendon(s); 2) making the osteotomy plane as parallel as possible to the ground surface; 3) adding a flexor-to-extensor tendon transfer; and 4) inserting a temporary Kirschner wire from the tip of the toe across the MTP joint and the osteotomy into the metatarsal (in a position of 5° plantarflexion). The Kirschner wire would prevent dorsiflexion of the MTP joint during the healing of the soft tissue. Clinical studies are underway to substantiate these clinical impressions. Scarring of the elongated plantar plate occurs after osteotomy but, provided vigorous manipulation of the toe (once the pin is removed at 2 to 3 weeks) is performed during recovery, the tendency to permanent second toe dorsiflexion contracture is minimized. The ability of this procedure to restore the balance of flexion and extension of the MTP joint in the clinical setting is currently under investigation.

## REFERENCES

1. Barouk, L. S.: Weil's metatarsal osteotomy in the treatment of metatarsalgia. *Orthopade*, **25**:338-344, 1996.
2. Bojsen-Moller, F.: Anatomy of the forefoot, normal and pathologic. *Clin. Orthop.*, **142**:10-18, 1979.
3. Coughlin, M. J.: Subluxation and dislocation of the second metatarsophalangeal joint. *Orthop. Clin. North Am.*, **20**:535-551, 1989.
4. Cracchiolo, A., III, Kitaoka, H. B., and Leventen, E. O.: Silicone implant arthroplasty for second metatarsophalangeal joint disorders with and without hallux valgus deformities. *Foot Ankle*, **9**:10-18, 1988.
5. Daly, P. J., and Johnson, K. A.: Treatment of painful subluxation or dislocation at the second and third metatarsophalangeal joints by partial proximal phalanx excision and subtotal webbing. *Clin. Orthop.*, **278**:164-170, 1992.
6. Deland, J. T., Lee, K. T., Sobel, M., and Dicarlo, E. F.: Anatomy of the plantar plate and its attachments in the lesser metatarsal phalangeal joint. *Foot Ankle Int.*, **16**:480-486, 1995.
7. Gould, J. S.: Metatarsalgia. *Orthop. Clin. North Am.*, **20**:553-562, 1989.
8. Muhlbauer, M., Trnka, H. J., Zembsch, A., and Ritschl, P.: Short-term outcome of Weil osteotomy in treatment of metatarsalgia. *Z. Orthop. Ihre Grenzgeb.*, **137**:452-456, 1999.
9. Sarrafian, S. K., and Topouzian, L. K.: Anatomy and physiology of the extensor apparatus of the toes. *J. Bone Joint Surg.*, **51A**:669-679, 1969.
10. Thompson, F. M., and Hamilton, W. G.: Problems of the second metatarsophalangeal joint. *Orthopedics*, **10**:83-89, 1987.
11. Trnka, H.-J., Muhlbauer, M., Zetti, R., Myerson, M. S., and Ritschl, P.: Comparison of the results of the Weil and Hehal osteotomies for the treatment of metatarsalgia secondary to dislocation of the lesser metatarsophalangeal joints. *Foot Ankle Int.*, **20**:72-79, 1999.