



Hallux valgus and cartilage degeneration in the first metatarsophalangeal joint

P. Bock,
K.-H. Kristen,
A. Kröner,
A. Engel

*From the Danube
Hospital, Vienna,
Austria*

This study relates the extent of cartilage lesions within the first metatarsophalangeal joint to hallux valgus.

We prospectively examined 265 first metatarsophalangeal joints of 196 patients with a mean age of 54.2 years at operation for the existence of cartilage lesions.

Grade I lesions were found in 41 feet (15.5%), grade II in 82 (30.9%), grade III in 51 (19.3%), grade IV in 20 (7.5%). Only 71 (26.8%) showed no cartilage lesion. Cartilage lesions were found within the metatarsosesamoid and metatarsophalangeal compartments in 66 feet (34.0%), within the metatarsophalangeal compartment in 26 (13.4%) and within the metatarsosesamoid compartment in 102 (52.6%). A statistically significant correlation was found between the grade of cartilage lesion and the hallux valgus angle, both for the changes within the metatarsophalangeal and the metatarsosesamoid joints.

Hallux valgus is common. It consists of lateral deviation of the hallux relative to the first metatarsal¹ and progressive subluxation of the first metatarsophalangeal joint.²

With progression of hallux valgus, clinical and radiological signs of osteoarthritis develop due to the increasing incongruity of the joint surfaces.^{1,3} As the sesamoids remain in place while the distal aspect of the first metatarsal displaces medially with progressive deformity, the metatarsosesamoid joint also shows incongruity. Cartilaginous thinning and erosion, joint space narrowing and marginal proliferation of bone occur. These cartilage lesions are often neglected.

Cartilage lesions are well documented in various other joints of the lower extremity.⁴ Osteoarthritis of the first metatarsophalangeal joint is usually related to hallux rigidus. There are only a few reports on cartilage degeneration in the first metatarsophalangeal joint^{4,5} without symptoms related to hallux rigidus.

Although osteoarthritis has been mentioned as a contraindication^{2,6,7} to joint preserving surgical procedures for the correction of hallux valgus, no report has been found of the incidence and extent of cartilage lesions within the first metatarsophalangeal joint. At operation no account is taken of the intra-operative grade of chondral lesion. This is why we carried out this study.

Patients and Methods

We prospectively examined 265 feet of 196 patients who were awaiting surgical correction of hallux valgus between 1998 and 2001. The series included 239 feet of 178 women and 26 feet of 18 men. The mean age at the time of surgery was 54.2 years (23 to 80). The symptoms were pain over the medial eminence and pressure from footwear. Surgery was proposed after failure of adequate non-operative treatment including wide shoes, inserts, orthoses and non-steroidal anti-inflammatory medication.

Every patient was assessed with regard to both the hind- and forefoot. The range of movement of the first metatarsophalangeal joint was measured and the patients examined for pain and crepitus in the first metatarsophalangeal and metatarsosesamoid joints which indicate degenerative joint disease. All patients with symptoms related to hallux rigidus with reduced dorsiflexion were excluded. The range of movement of the first metatarsophalangeal joint was more than 40° dorsiflexion in all patients.

Exclusion criteria included any prior surgery or trauma to the first metatarsophalangeal joint or foot, and typical symptoms of hallux rigidus such as pain with movement and limited dorsiflexion,⁸ peripheral vascular disease and metabolic or endocrine disorders which could affect the articular cartilage.

■ P. Bock, MD, Resident
■ K.-H. Kristen, MD, Consultant
■ A. Kröner, MD, Resident
■ A. Engel, PhD, Head of Department
Department of Orthopaedic Surgery, Donauspital Wien, Langobardenstrasse 122, A-14766 Wien, Austria.

Correspondence should be sent to Dr P. Bock.

©2004 British Editorial Society of Bone and Joint Surgery
doi:10.1302/0301-620X.86B5.14766 \$2.00

J Bone Joint Surg [Br]
2004;86-B:669-73.
Received 3 July 2003;
Accepted after revision
3 December 2003

Pre-operative anteroposterior and lateral radiographs of the feet were taken with the patient weight-bearing. The degree of radiological osteoarthritic change was determined by a single experienced radiologist according to a modified Kellgren-Lawrence scale⁵ as follows: grade 0 = normal; grade 1 = mild osteophytic lipping, no sclerosis; grade 2 = moderate osteophytic lipping with or without osteophytic lipping; grade 3 = multiple osteophytic lipping, some sclerosis, and possible deformity of bone contour; grade 4 = severe osteophytes, sclerosis and deformity of the bony contour. Measurement of the alignment of the fore-foot was performed according to the guidelines accepted by the American Orthopaedic Foot and Ankle Society.⁹ The following radiological criteria were assessed: hallux valgus angle and the angle between the first and second metatarsals (intermetatarsal angle).^{10,11}

Joint preserving procedures were performed in all patients. A longitudinal midline skin incision was made on the medial side of the first metatarsophalangeal joint.

The joint capsule and the medial collateral ligament of the first metatarsophalangeal joint were incised horizontally and the articular cartilage exposed. The cartilage lesions on the metatarsal head were noted and graded according to the International Cartilage Repair Society¹² (ICRS) as follows (Fig. 1): grade 0 = normal; grade I = nearly normal, superficial lesions, soft indentation and/or superficial fissures and cracks; grade II = abnormal, lesions extending down to <50% of cartilage depth; grade III = severely abnormal, cartilage defects extending down >50% of cartilage depth as well as down to the calcified layer and to but not through the subchondral bone; grade IV = severely abnormal, cartilage defect extending through the subchondral bone. Three different zones were differentiated: metatarsal head articulating with the proximal phalanx (metatarsophalangeal compartment), metatarsal head articulating with the medial sesamoid bone and metatarsal head articulating with the lateral sesamoid bone (metatarsosesamoid compartments). The medial and lateral metatarsosesamoid joints together and the metatarsophalangeal compartment each contributed 50% of the cartilage surface.

The data were analysed for correlation of grade and localisation of the cartilage lesion and hallux valgus angle and the first intermetatarsal angle by Spearman's correlation test, paired student's *t*-test and linear regression (Statview 5.5; SAS Institute Inc, Cary, North Carolina). The level of statistical significance was set at $p < 0.05$.

Results

The hallux valgus angle and the mean intermetatarsal angle was 29.4° (15 to 60) and 13.5° (10 to 25) respectively pre-operatively.

Of the 265 feet examined for cartilage lesions, 71 (26.8%) did not have any lesion, 41 (15.5%) had a maximum grade I lesion, 82 (30.9%) a maximum grade II lesion, 51 (19.3%) a maximum grade III lesion and 20 feet (7.5%)

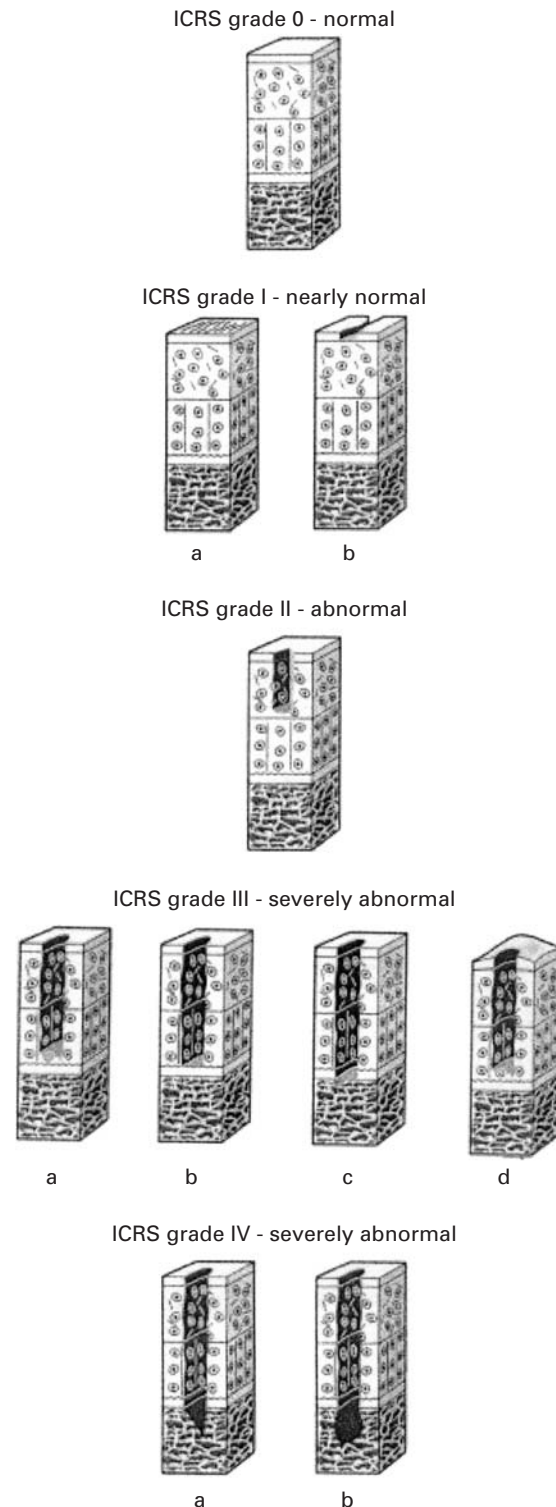


Fig. 1

Grading of cartilage lesion according to the International Cartilage Repair Society (reproduced with permission from the International Cartilage Repair Society). Grade 0 – normal; grade I – nearly normal, superficial lesions a) soft indentation and/or b) superficial fissures or cracks; grade II – abnormal, lesions extending down to <50% of cartilage depth; grade III – severely abnormal. a) Cartilage defects extending down >50% of cartilage depth b) as well as down to calcified layer c) down to but not through the subchondral bone d) blisters are included; grade IV – severely abnormal.

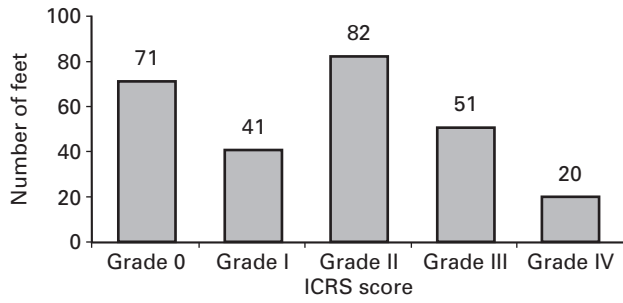


Fig. 2

Grade of chondral lesion at time of surgery according to ICRS score.

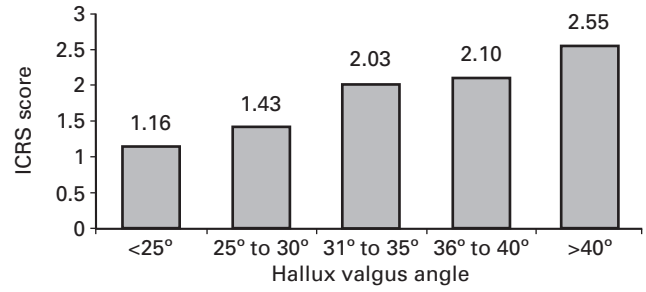


Fig. 4

Mean grade of chondral lesion according to the ICRS score for an increasing hallux valgus angle.

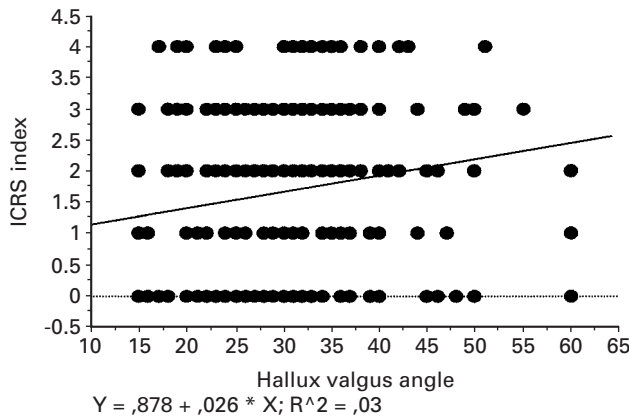


Fig. 3

Hallux valgus angle versus grade of cartilage lesion (ICRS score). As the hallux valgus angle increases the grade of cartilage lesion increases. A correlation coefficient of 0.03 quantifies this relationship.

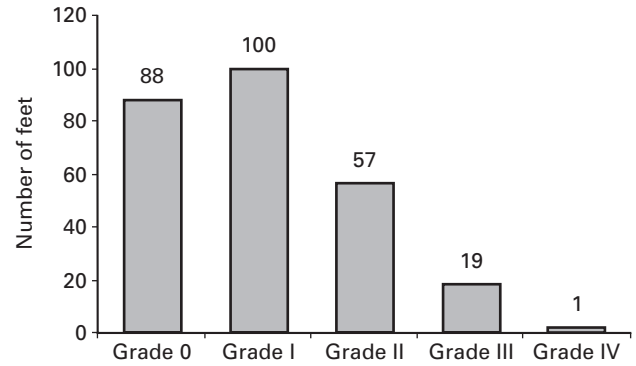


Fig. 5

Radiological scoring of pre-operative osteoarthritis according to a modified Kellgren-Lawrence scale (grade 0 to grade IV).

a maximum grade IV lesion within one of the three compartments (Fig. 2).

In 93 feet (35.1%) cartilage lesions were found on the head of the first metatarsal within the metatarsophalangeal compartment, in 166 (62.6%) lesions were found on the metatarsal head within the medial metatarsosesamoid compartment and in 155 (58.5%) they were on the metatarsal head within the lateral metatarsosesamoid compartment. In the metatarsosesamoid joint (170 feet), lesions were found concomitantly in the medial and lateral sides in 151 feet (88.8%), medially in 15 (8.8%) and laterally in four (2.4%).

Of the 194 feet with cartilage lesions, 102 (52.6%) had a lesion within the metatarsosesamoid compartment, 26 (13.4%) within the metatarsophalangeal compartment and 66 (34.0%) in both zones.

The mean maximum grade of cartilage lesion did not show a statistically significant difference in the three compartments with a mean of 2.18 within the metatarsophalangeal compartment, 2.18 in the medial metatarsosesamoid

compartment and 2.16 in the lateral metatarsosesamoid compartment ($p > 0.05$).

Spearman's correlation test showed a statistically significant correlation between the maximum chondral lesion grade and the hallux valgus angle ($p < 0.001$, $r = 0.03$) (Fig. 3). The higher the hallux valgus angle the higher the grade of cartilage lesion. If grades of cartilage lesion of the different compartments in one joint were added, a highly statistically significant correlation was found for the sum of cartilage lesions and the hallux valgus angle ($p < 0.001$, $r = 0.047$) and for the intermetatarsal angle ($p < 0.0001$, $r = 0.075$).

For a hallux valgus angle less than 25° the mean maximum grade of cartilage lesion was 1.16, 1.43 for an angle between 25° and 30°; 2.03 for an angle between 31° and 35°; 2.10 for an angle between 36° and 40°; and 2.55 for an angle greater than 40° (Figs 4 and 5, Table I).

Radiological examination according to a modified Kellgren-Lawrence Scale⁵ showed 88 feet (33.2%) at grade 0, 100 (37.7%) at grade I, 57 (21.5%) at grade II, 19 (7.2%)

Table I. Hallux valgus angle and percentage of feet affected by different grades of chondral lesion

Hallus valgus angle	< 25° (%)	25° to 30° (%)	31° to 35° (%)	36° to 40° (%)	> 40° (%)
grade 0	42	32.1	17.0	10.3	4.5
grade I	21.7	12.3	8.4	24.1	13.6
grade II	18.9	38.3	39.0	24.1	31.8
grade III	14.9	14.8	25.4	27.7	22.8
grade IV	2.5	2.5	10.2	13.8	27.3

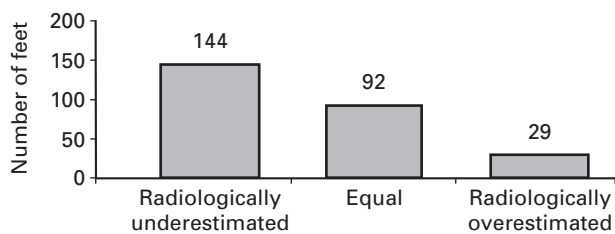


Fig. 6

Radiological (Kellgren-Lawrence) versus intra-operative (ICRS) score.

at grade III and 1 (0.4%) at grade IV (Fig. 5). Compared with the intra-operative grading on the ICRS¹² score 144 feet (54.3%) had a lower radiological than intra-operative score, 92 (34.7%) had an equal score and 29 (11.0%) a higher radiological than intra-operative score (Fig. 6).

Discussion

Only 26% of all joints did not show any cartilage lesion within the joint, and approximately 60% of all feet revealed lesions of grade II or higher. Cartilage lesions of grade II and III were the most frequent (Fig. 2).

Unger et al⁵ did not find any metatarsal heads without a cartilage lesion. There were 18.2% with grade I, 33.3% with grade II, 35.4% with grade III and 13.1% with grade IV lesions. They used a similar classification system to ours. These results are not directly comparable as Unger et al⁵ performed a cadaver study and the mean age, 73.6 years for men and 77.8 years for women was higher than in this study. In addition, these authors did not specifically address the problem of hallux valgus. A correlation between the intermetatarsal angle and the grade of cartilage lesion was found in women but the radiological assessment did not include standard radiographs in a weight-bearing position. The sites of cartilage lesions within the joint were not recorded.⁵ Our study demonstrates a clear tendency towards cartilage lesions within the metatarsosesamoid compartment of the first metatarsophalangeal joint. Nearly two thirds of all feet had a cartilage lesion within the metatarsosesamoid compartment compared with more than one third in the metatarsophalangeal compartment. The grade of cartilage lesions did not differ significantly.

Most of the joints had cartilage lesions within both the medial and lateral parts of the metatarsosesamoid com-

partment. These findings indicate that the load pattern changes within the first MTP joint, affect the metatarsosesamoid compartment, both laterally and medially, and then the metatarsophalangeal compartment of the joint. The fact that kinematics are changed within all compartments with hallux valgus was shown by Shereff et al.¹³ They stated that the metatarsophalangeal joints of feet in hallux valgus displayed irregularities in the kinematic pattern compared with normal joints. Both the grade of cartilage lesion within the metatarsophalangeal and the metatarsosesamoid compartments were positively correlated with an increase of the hallux valgus angle. Thus, the probability of cartilage lesions within the first metatarsophalangeal joint becomes higher with an increasing hallux valgus angle.

Different cartilage characteristics do not seem to play a major role in relation to where chondral lesions will develop. Athanasiou et al¹⁴ did not find a mismatch in the mechanical properties of the cartilage surface of the different zones within the first metatarsophalangeal joint.

The pre-operative radiological examination underestimated the grade of chondral lesion in more than 50% of all feet. The metatarsosesamoid compartment was difficult to assess. Many surgeons thus choose their operation according to the degree of radiological degeneration without knowing the exact extent of the degenerative changes.

Osteoarthritis within the first metatarsophalangeal joint is considered a contraindication to joint preserving surgical procedures.^{2,6,7} There has not been a report which graded the cartilage lesions within the first MTP joint in hallux valgus or stated to what extent cartilage lesions can be accepted when performing joint preserving surgery for the correction of hallux valgus. Mann, Rudicel and Graves¹⁵ reported that in 81 feet (74%) of their series no osteoarthritis was diagnosed pre-operatively. He does not give any information about the remaining joints.

Until now no correlation has been drawn between the extent of cartilage lesion and the possible influence on the outcome of hallux valgus surgery. Therefore it is important to have an idea of the incidence of cartilage defects in order to evaluate its influence. Kristen et al¹⁶ described a correlation between a higher pre-operative hallux valgus angle and the post-operative Kitaoka et al¹⁷ score. The higher the pre-operative hallux valgus angle, the lower the post-operative score. The authors could not give any explanation for this trend. The answer to this question might lie with the higher probability for cartilage lesions with a greater hallux valgus angle, as shown in this study, or a higher age range and thus a worse post-operative result. Further studies are required for clarification.

There were more cartilage lesions within the metatarsosesamoid compartment than within the metatarsophalangeal compartment. The degree and extent of cartilage lesions are clearly correlated with the degree of hallux valgus angle proving that a malaligned joint is more prone to cartilage degeneration.

These results provide further evidence of a possible effect of cartilage degeneration on the outcome of hallux valgus surgery.

The effects of metatarsal osteotomy on the first metatarsophalangeal joint may be similar to those of tibial osteotomy on the knee.

No benefits in any form have been received or will be received from any commercial party related directly or indirectly to the subject of this article.

References

1. **Jahss MH.** The adult foot. In: Jahns MH, ed. *Disorders of the foot and ankle: medical and surgical management*. 2nd edition, Vol 2. Philadelphia: W.B. Saunders Company, 1991:943-1174.
2. **Coughlin MJ.** Hallux valgus. *J Bone Joint Surg [Am]* 1996;78-A:932-66.
3. **Weingeld SB, Schon LC.** Hallux metatarsophalangeal arthritis. *Clin Orthop* 1998; 349:9-19.
4. **Muehleman C, Bareither D, Huch K, Cole AA, Kuether KE.** Prevalence of degenerative morphological changes in the joints of the lower extremity. *Osteoarthritis cartilage* 1997;5:23-37.
5. **Unger K, Rahimi F, Bareither D, Muehleman C.** The relationship between articular cartilage degeneration and bone changes of the first metatarsophalangeal joint. *J Foot Ankle Surg* 2000;39:24-32.
6. **Wülker N.** Hallux valgus. *Orthopaede* 1997;26:654-64.
7. **Mann RA.** Decision-making in bunion surgery. *Instr Course Lect* 1990;39:3-13.
8. **Shereff MJ, Baumhauer JF.** Hallux rigidus and osteoarthritis of the first metatarsophalangeal joint. *J Bone Joint Surg [Am]* 1998;80-A:898-908.
9. **Smith RW, Reynolds JC, Steward MJ.** Hallux valgus assessment: report of research committee of American Foot and Ankle Society. *Foot Ankle* 1984;5:92-103.
10. **Schneider W, Knahr K.** Metatarsophalangeal and intermetatarsal angle: different values and interpretation of postoperative results dependent on the technique of measurement. *Foot Ankle Int* 1998;19:532-6.
11. **Mitchell CL, Fleming JL, Allen R, Glenney C, Sanford GA.** Osteotomy-bunionectomy for hallux valgus. *J Bone Joint Surg [Am]* 1958;40-A:41-60.
12. **International Cartilage Research Society.** The cartilage standard evaluation form. Spring Newsletter 1998.
13. **Shereff MJ, Bejjani FJ, Kummer FJ.** Kinematics of the first metatarsophalangeal joint. *J Bone Joint Surg [Am]* 1986;68-A:392-8.
14. **Athanasίου KA, Liu GT, Lavery LA, Lanctot DR, Schenck RC.** Biomechanical topography of human articular cartilage in the first metatarsophalangeal joint. *Clin Orthop* 1998;348:269-81.
15. **Mann RA, Rudicel S, Graves SC.** Repair of hallux valgus with a distal soft-tissue procedure and proximal metatarsal osteotomy: a long-term follow-up. *J Bone Joint Surg [Am]* 1992;74-A:124-9.
16. **Kristen KH, Berger C, Stelzig S, et al.** The SCARF osteotomy for the correction of hallux valgus deformities. *Foot Ankle Int* 2002;23:221-9.
17. **Kitaoka HB, Alexander IJ, Adelaar RS, et al.** Clinical rating systems for ankle-hindfoot, midfoot, hallux, and lesser toes. *Foot Ankle Int* 1994;15:349-53.